

Dental Abfractions

Brian Palmer, D.D.S

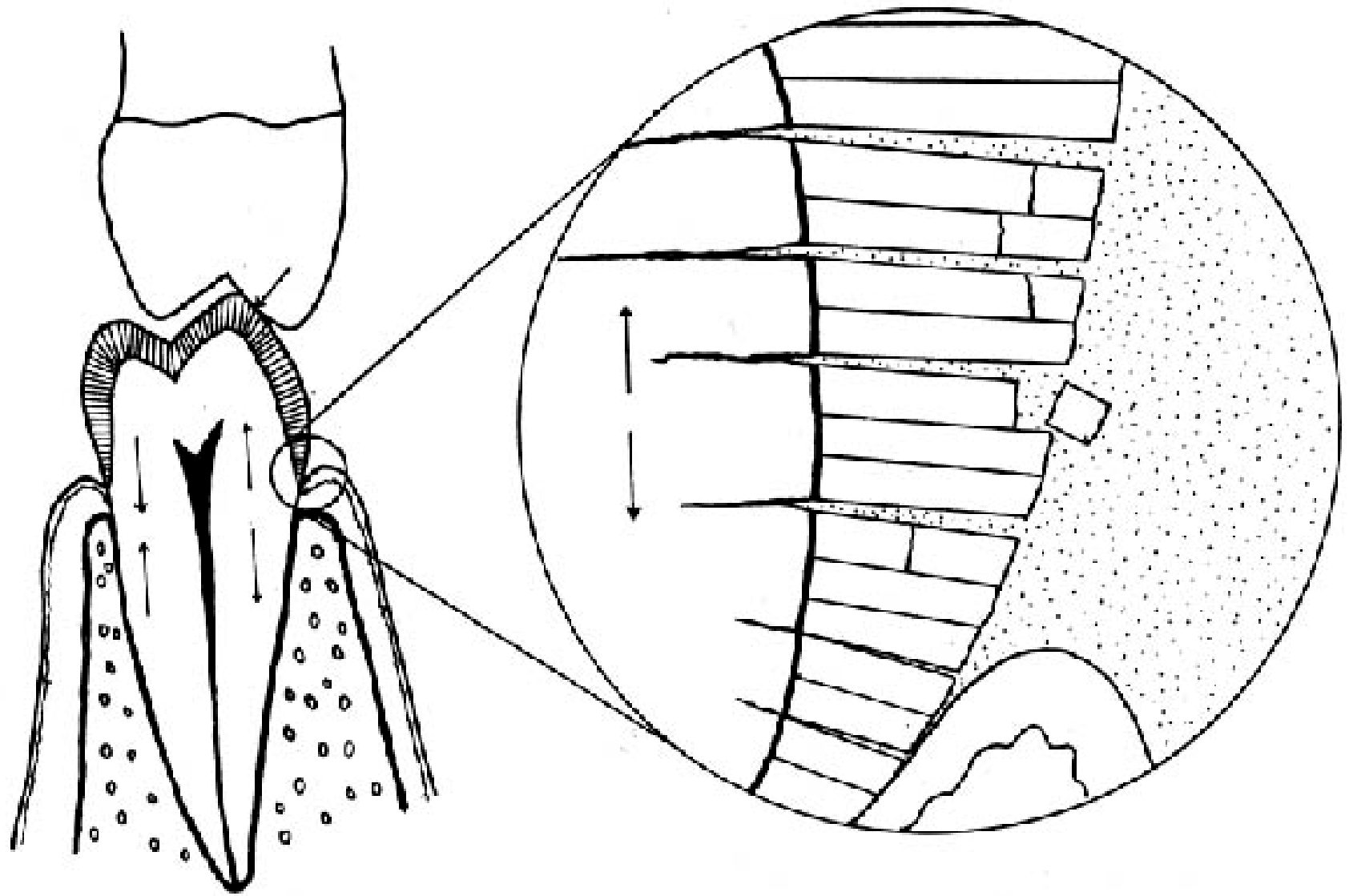


Fig 1

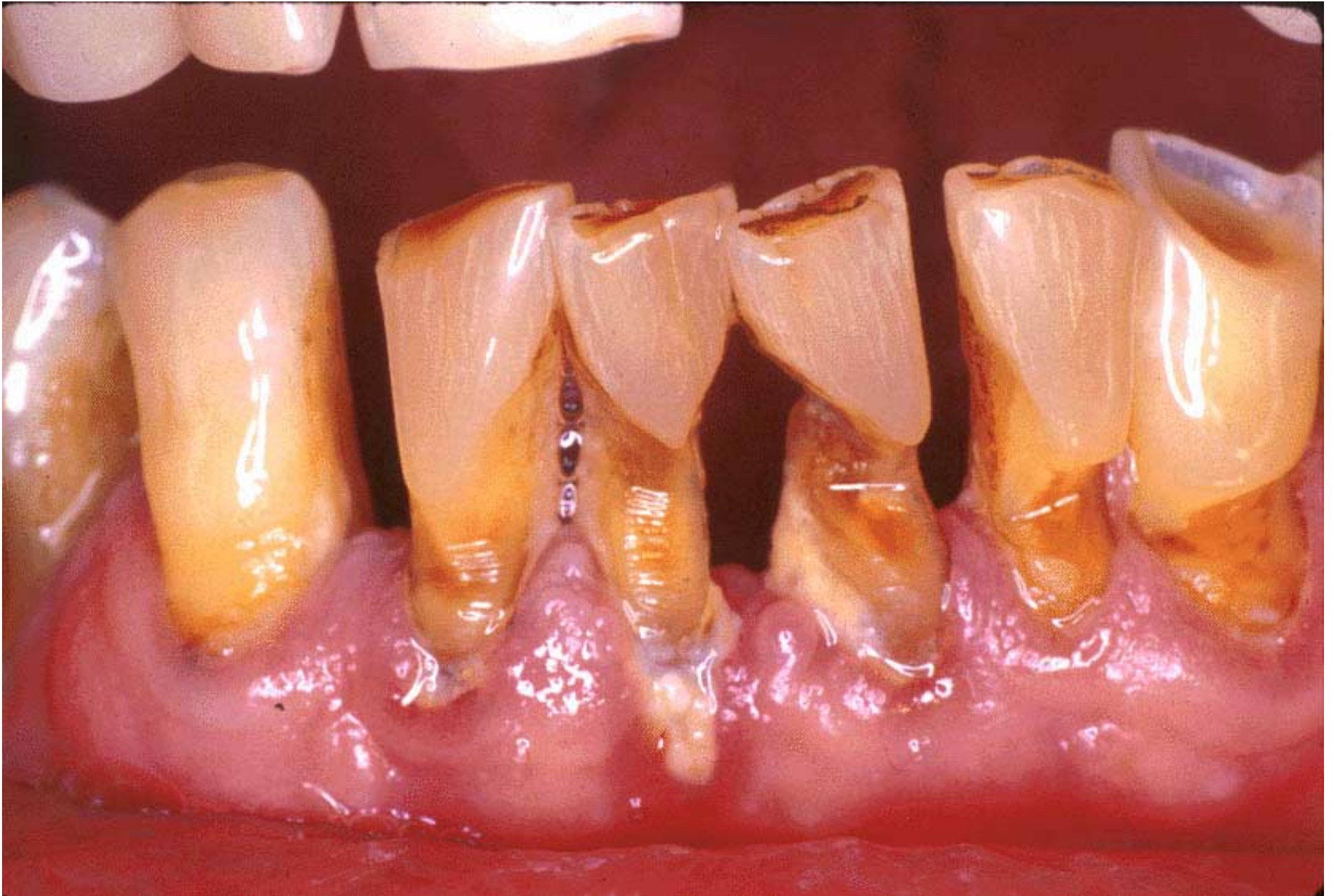

Fig 2a

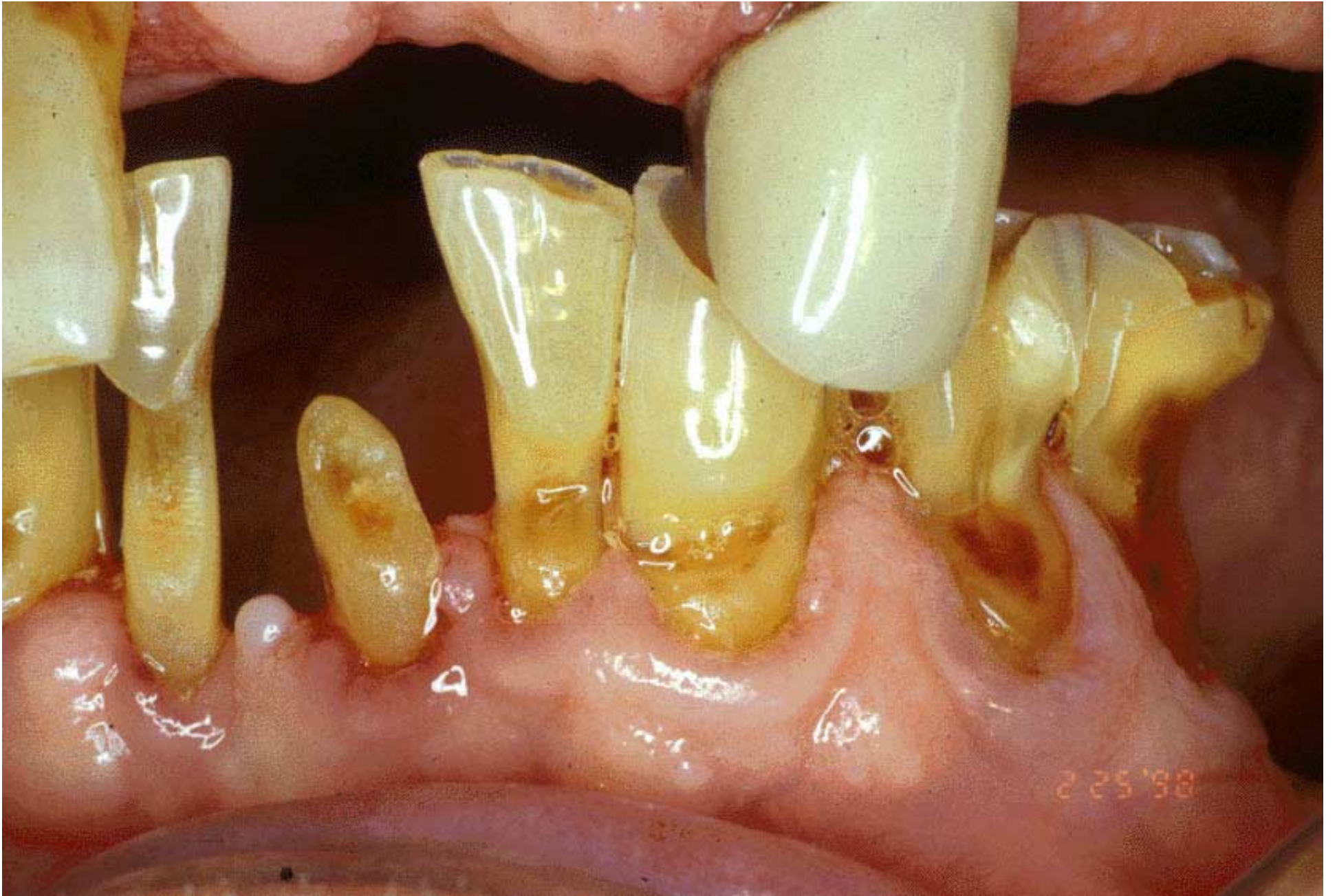

Fig 2b

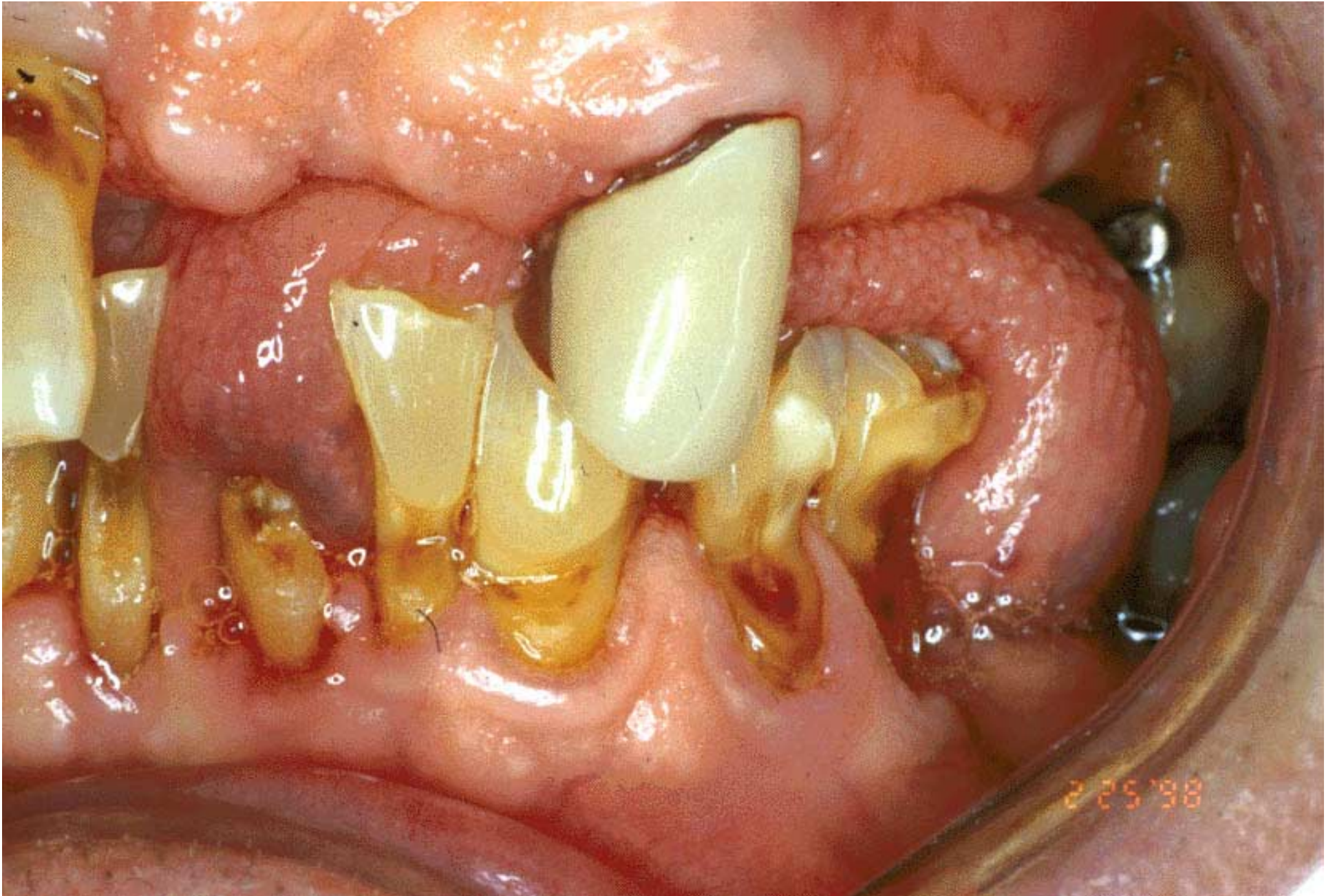


Fig 2c

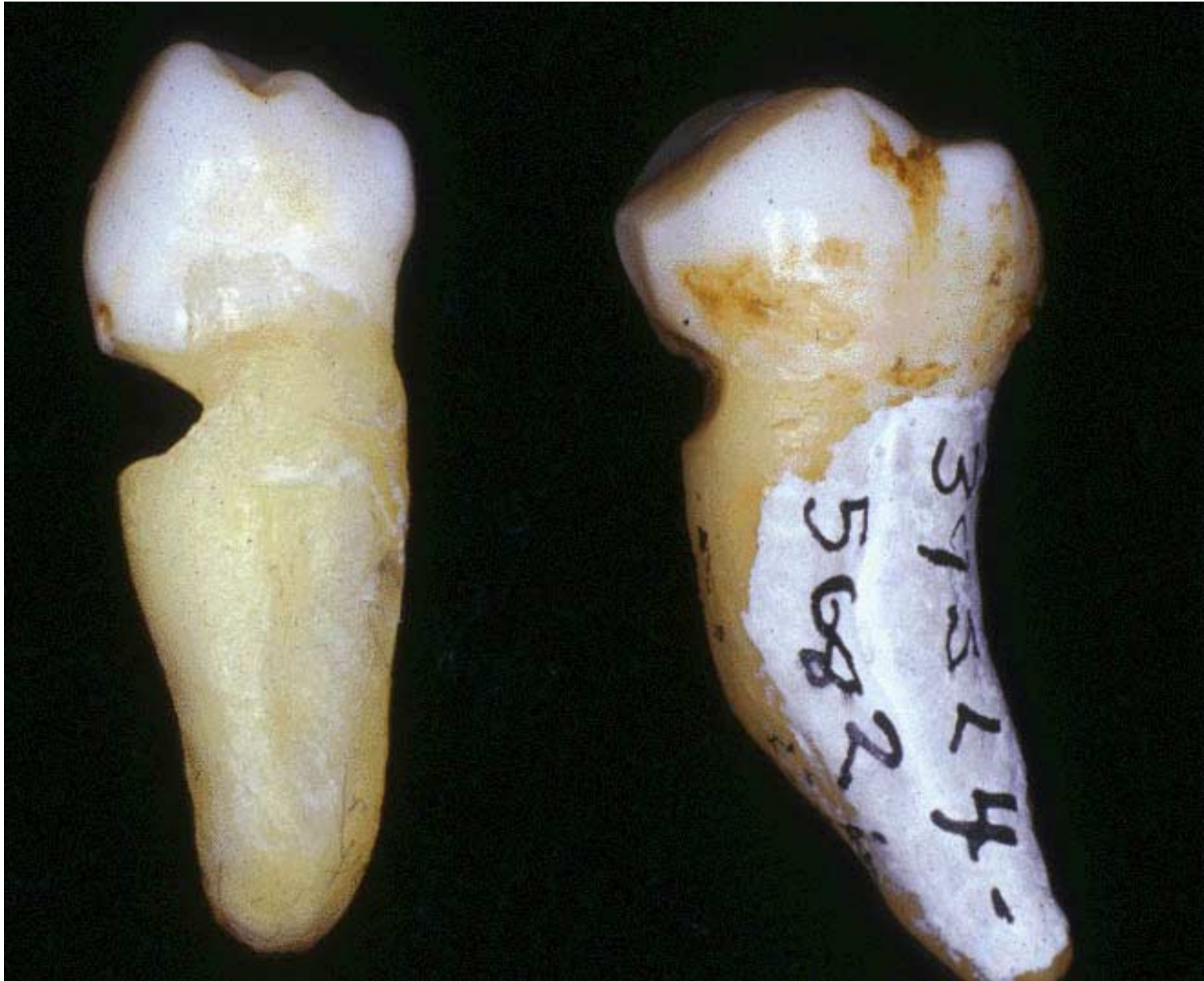

Fig 3

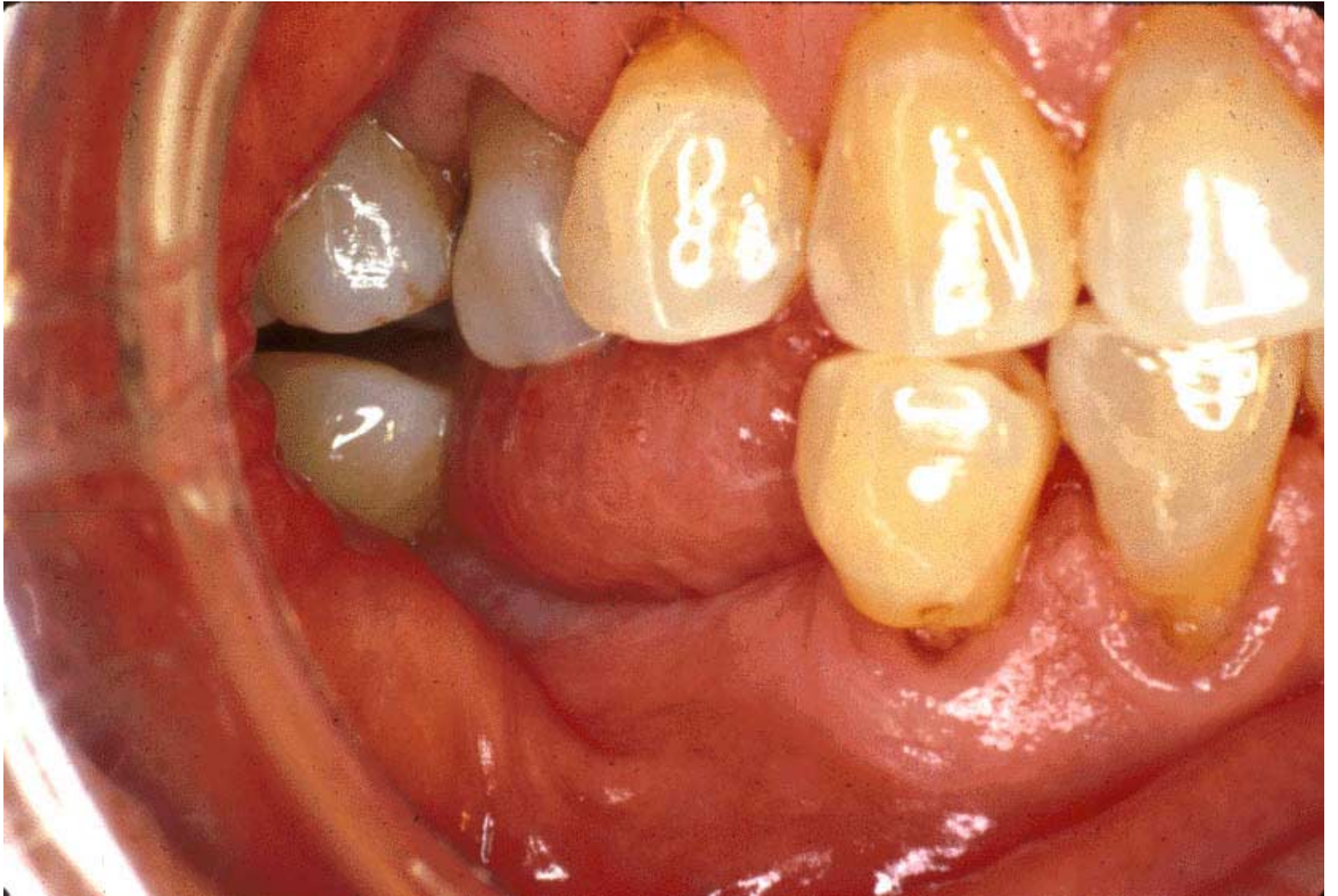


Fig 4a

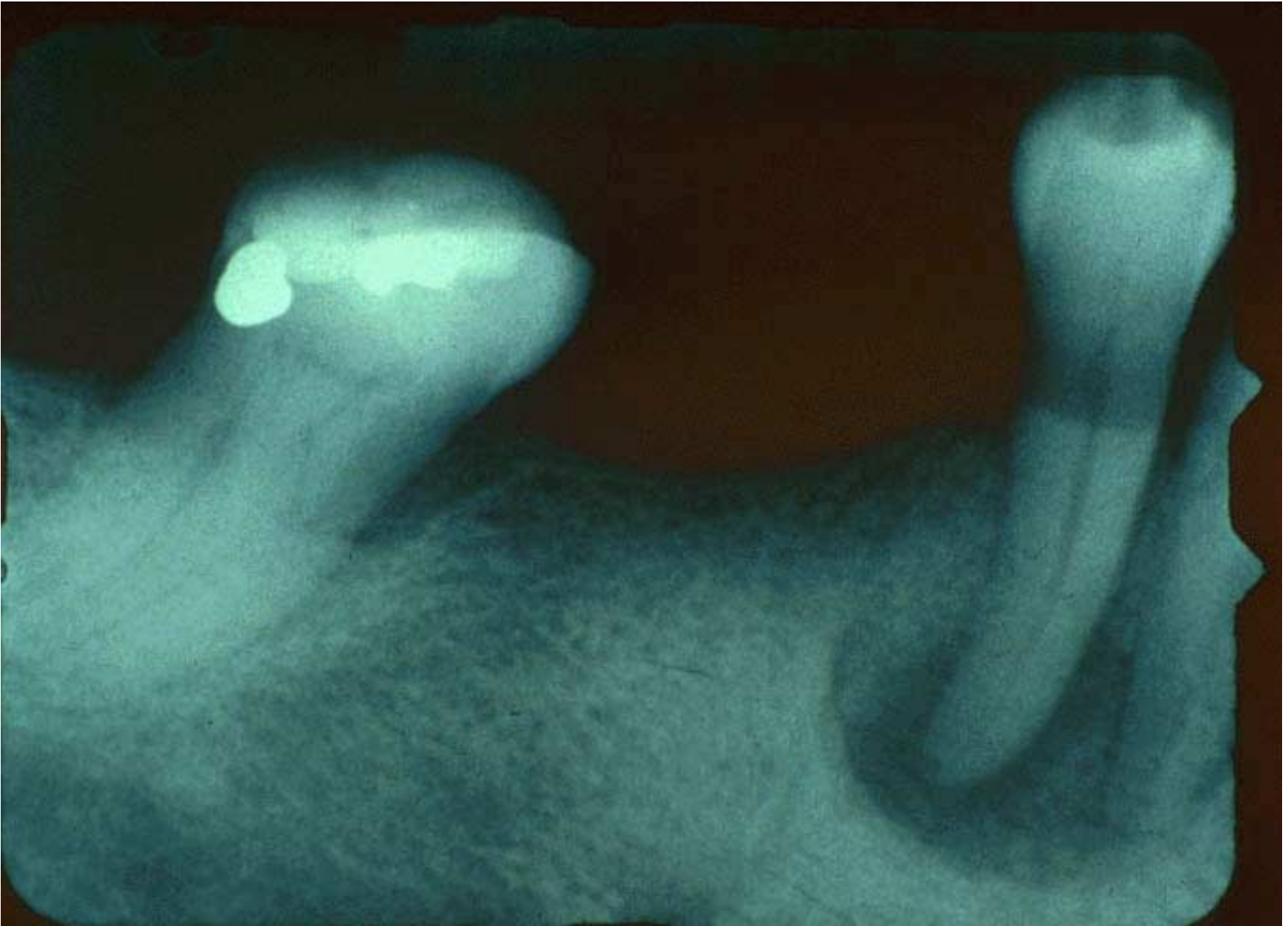


Fig 4b