


Occlusion

- ❖ The **KEY** to dentistry.
- ❖ The **KEY** to total health.
- ❖ The **KEY** to this website.

Basics of Occlusion

Simplistic definition of occlusion:
The way teeth meet and function.


EVALUATION,
DIAGNOSIS, AND
TREATMENT OF
OCCLUSAL PROBLEMS



PETER E. DAWSON

The **BEST** textbook on
dentistry. Every dentist
should read.

Peter E. Dawson. Evaluation,
Diagnosis, and Treatment of
Occlusal Problems, 2nd ed.. Mosby.



I am standing beside, in my opinion, one of the best dentists in the world, Dr. Peter Dawson.

Centric Relation (CR)

Refers to the RELATIONSHIP of the **MANDIBLE TO THE SKULL** as it rotates around the ‘hinge-axis’ before any translatory movement of the condyles from their “upper-most and mid-most position”. It is irrespective of tooth position or vertical dimension.

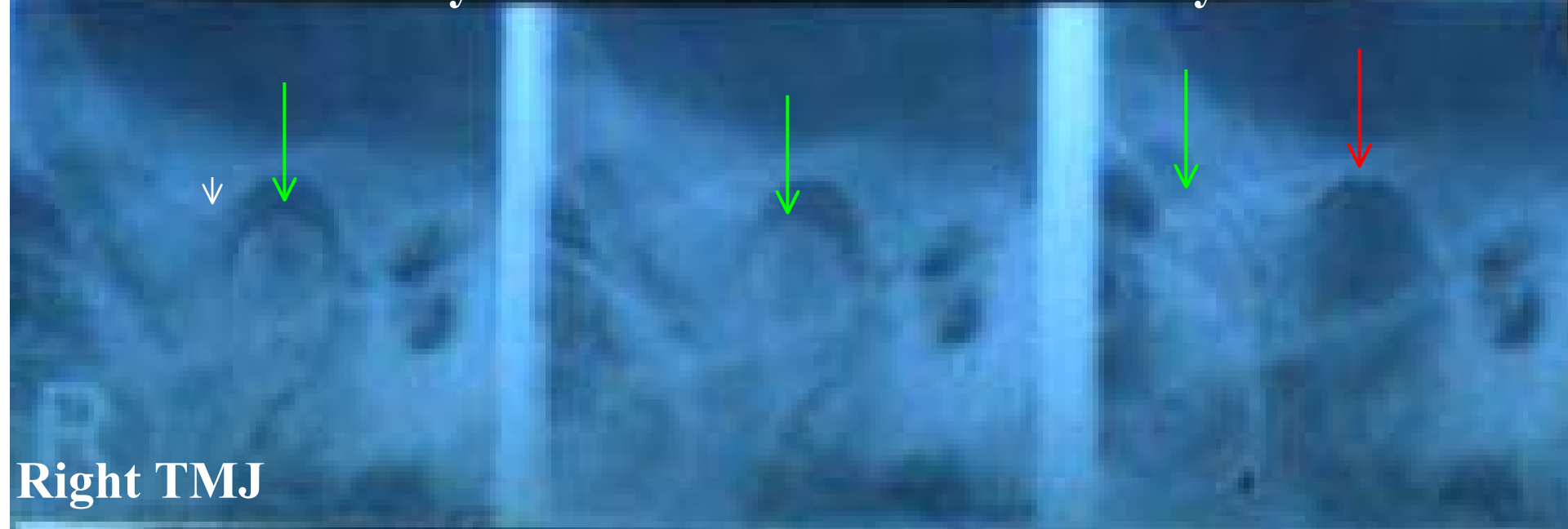
Peter E. Dawson. Evaluation, Diagnosis, and Treatment of Occlusal Problems, 2nd ed.. Mosby.



Left TMJ

Condyles in socket.

Condyles advanced.



Right TMJ

A6 Transcranial radiograph of TMJ.

Green arrows: Head of condyle.
White arrows: Articular tubercle.
Red arrows: Glenoid fossa.

Condyle: The rounded articular surface at the end of the mandible (lower jaw).

Glenoid fossa: A deep concavity in the temporal bone at the root of the zygomatic arch that receives the condyle of the mandible.

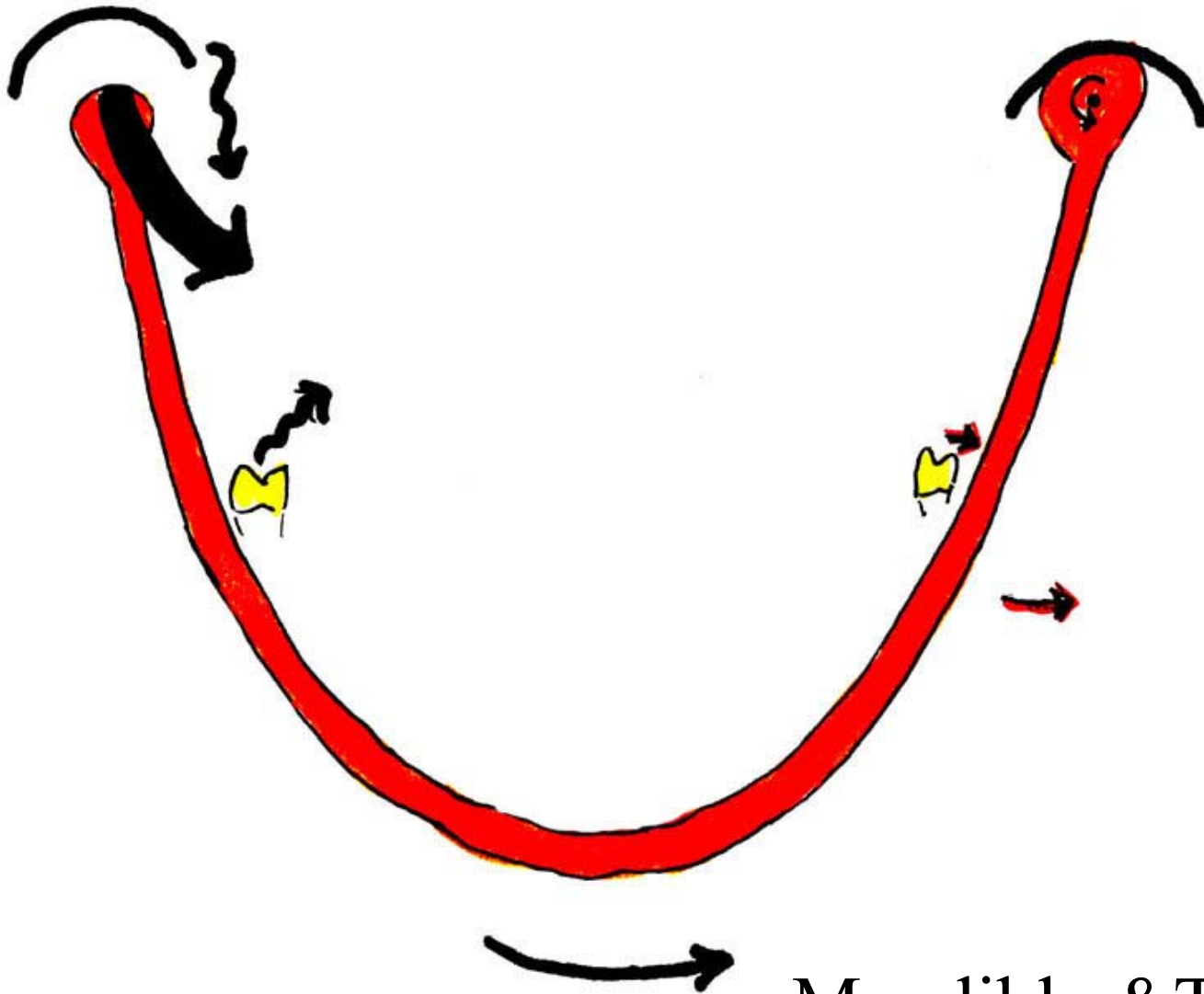
Tubercle: A slight elevation from the surface of the bone giving attachment to a muscle or ligament.

Balancing side.

Condyle has downward path.

Working side.

Condyle pivots.



Mandible & TMJ

Working side: (Mandible moving toward the cheek)

Working side condyle pivots within the socket and is better supported.

Balancing side: (Mandible moving toward the tongue)

Balancing side condyle has a downward orbiting path. It is traveling a greater distance in 'space' and is more prone to injury or damage.

Centric Occlusion (CO)

Refers to the RELATIONSHIP of the **MANDIBLE TO THE MAXILLA** when the teeth are in maximum occlusal contact, irrespective of the position or alignment of the condyle-disk assemblies.

Peter E. Dawson. Evaluation, Diagnosis, and Treatment of Occlusal Problems, 2nd ed.. Mosby.

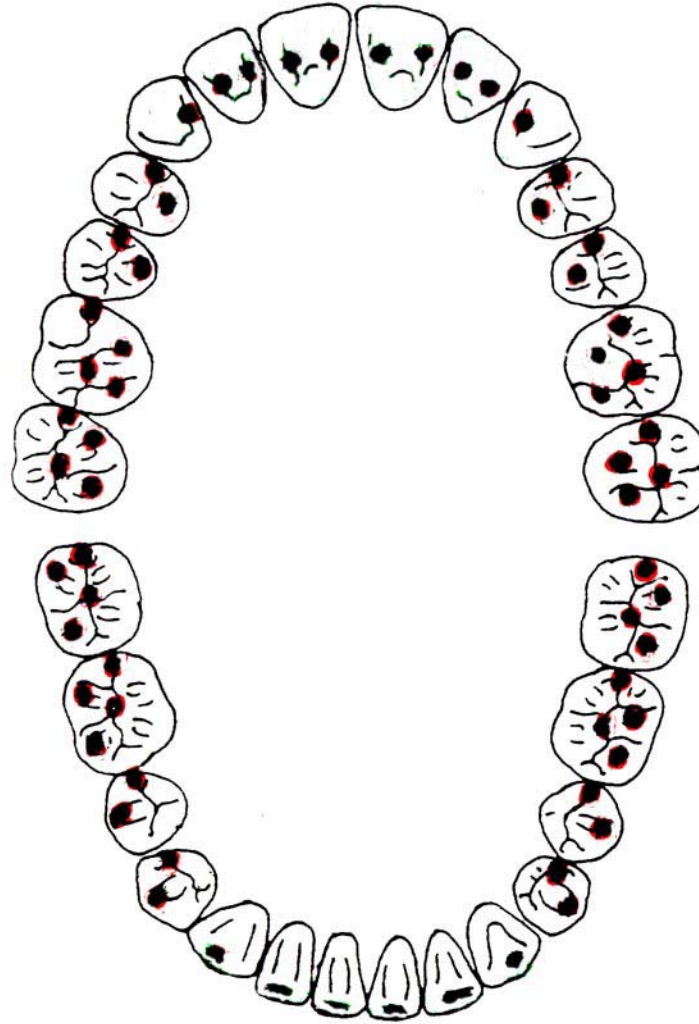
Five requirements of a stable occlusion.

Peter E. Dawson. Evaluation, Diagnosis, and Treatment of Occlusal Problems, 2nd ed.. Mosby. Chapter 27, p470-476.

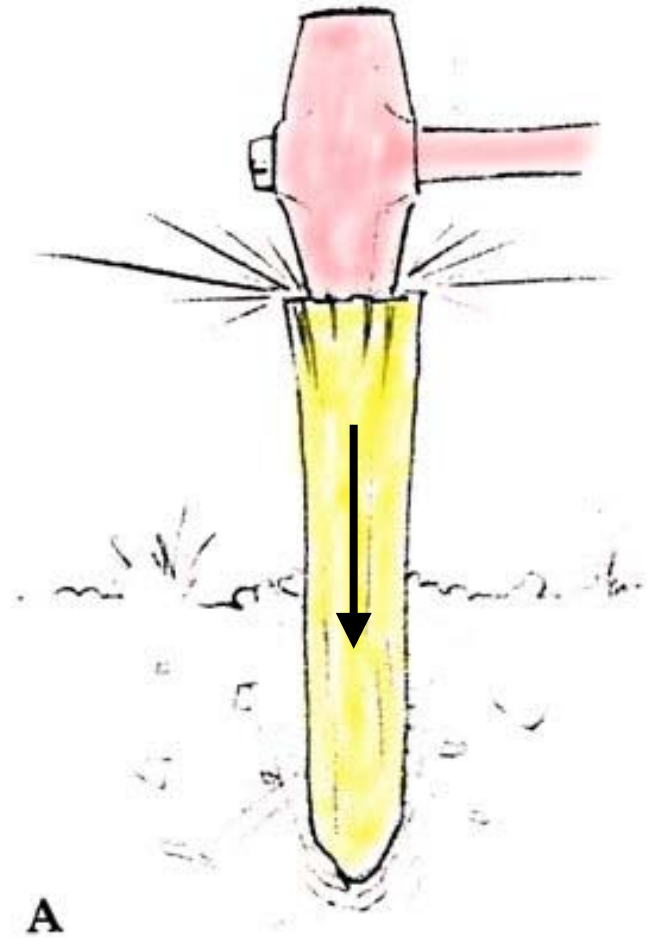
1. **Stable stops on all the teeth** when the condyles are in Centric Relation (CR).

Centric Stops

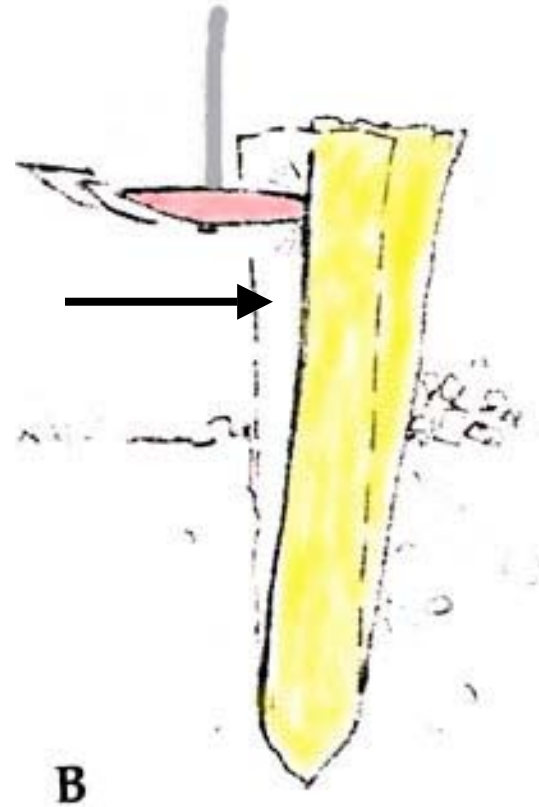
Point contacts are on
lingual cusp tips of
maxillary posterior teeth,
buccal cusp tips of
mandibular posterior
teeth, central pits or
marginal ridges on
posterior teeth, incisors
of lower anteriors and
linguals of upper
anteriors.



Note 'U' shape of dental arches.



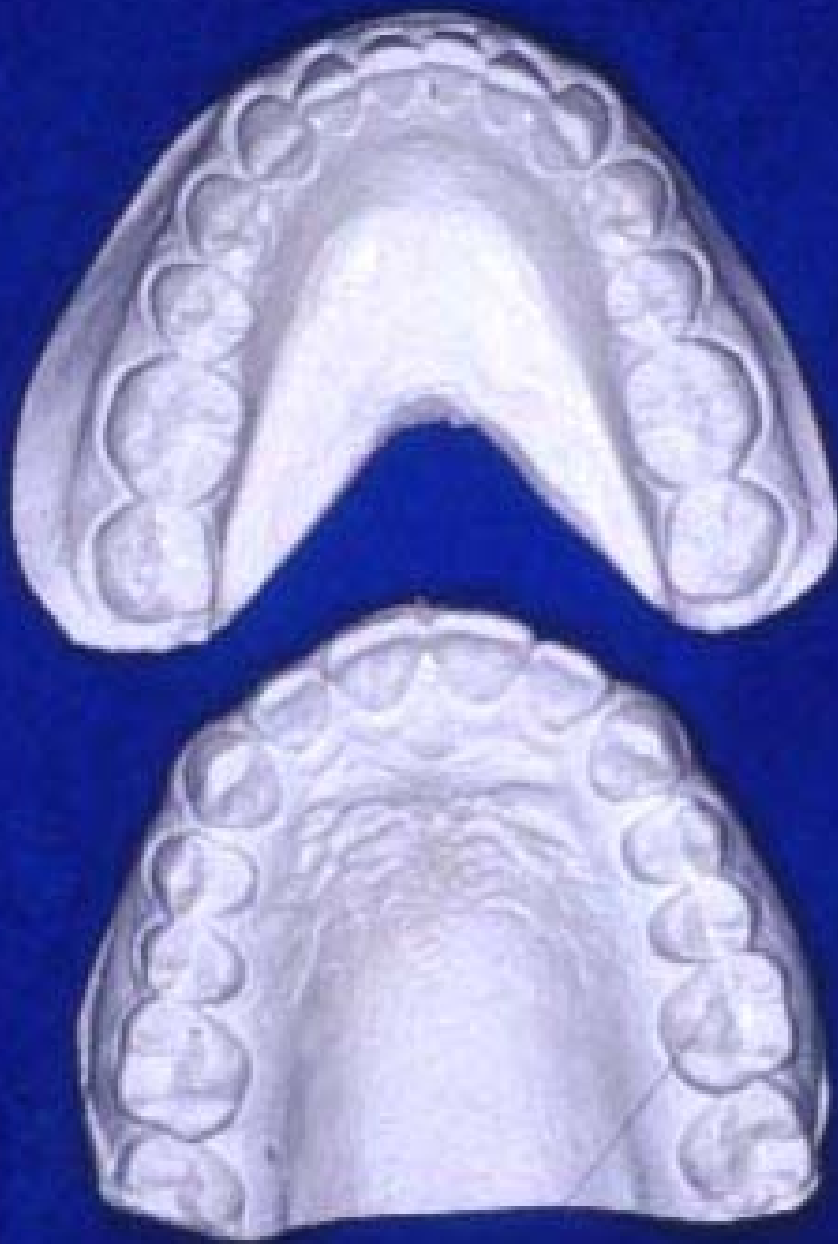Teeth are designed to absorb heavy forces in the direction of the **long axis** of the tooth.



Most teeth are not designed to absorb damaging **lateral** forces.

Ideal bite

- Should have **point contacts** of the **maxillary posterior lingual cusp tips** and the **mandibular posterior buccal cusp tips** to the central fossa or marginal ridges of opposing posterior teeth.
- Forces exerted on the posterior teeth should be directed through the **long axis of the teeth**.
- ‘Normal’ buccal positioning of the maxillary buccal cusps should be ‘outside’ or buccal to the mandibular teeth.



Note 'U' shape
of dental arches.

To naturally accommodate all the
teeth in an ideal bite relationship,
the arches need to have a 'U'
shape (as apposed to a 'V'
shape).

2. Anterior Guidance in harmony with the border movements of the **Envelope of Function.**

Note **angulation** of the maxillary anterior tooth (red arrow).


Most normal chewing stays within the red area, but the lower teeth have the range of the black line.



Lower teeth are 'guided' by a gentle slanted slope of the upper lingual surfaces.

Envelope of function

Mal-aligned cuspid.

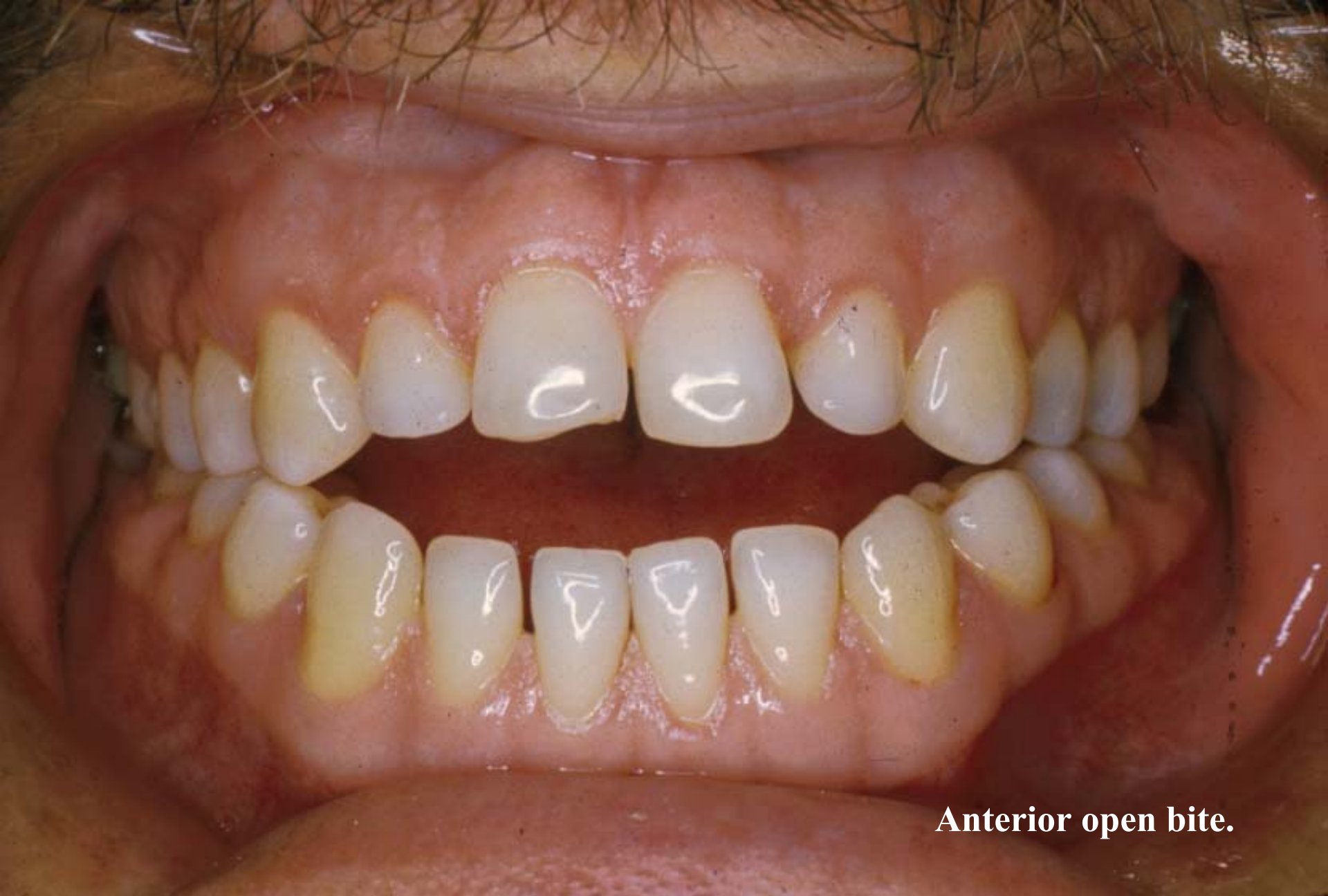

Too upright. Should have position of dotted tooth.

A too upright tooth interferes with the “Envelope of Function”.

3. Disclusion (separation) of all the **posterior (back) teeth** in protrusive (forward) movements by the **MOST ANTERIOR** (front) teeth (Anterior Guidance).

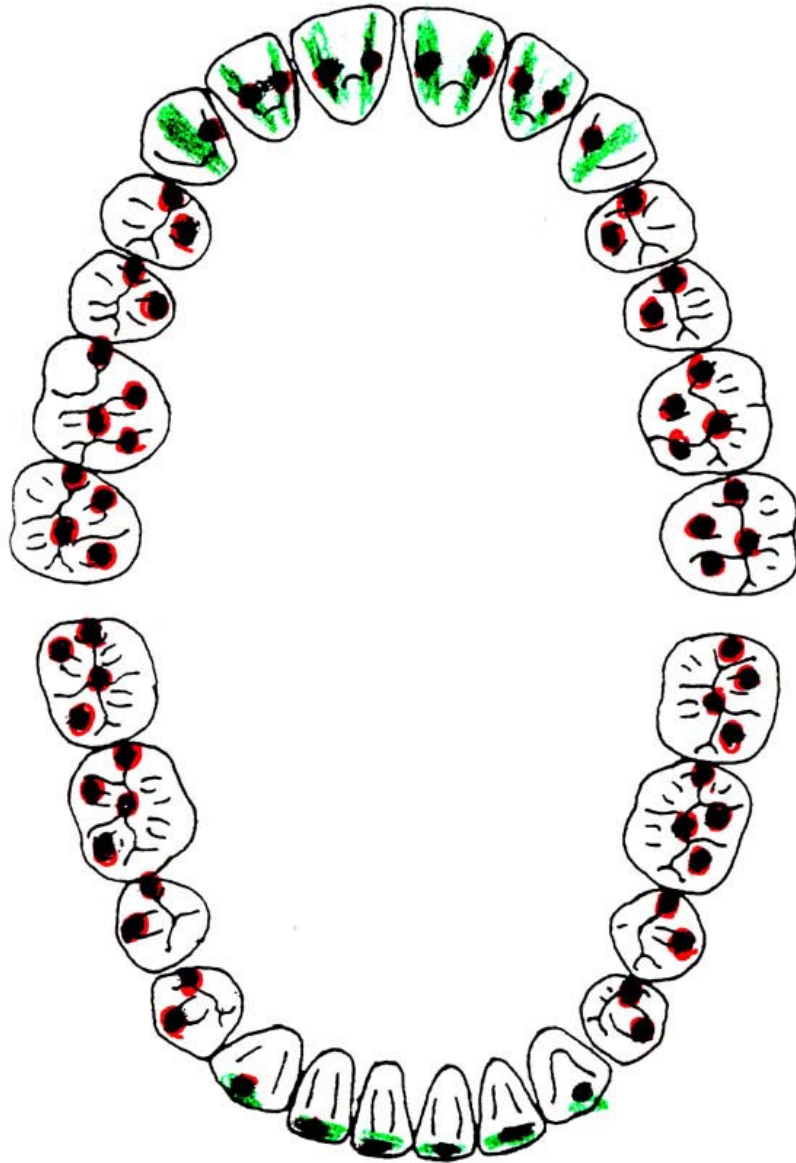
Ideally this should be the 6 front teeth, but in some cases of an open bite for example, the most anterior tooth could be a bicuspid.



Anterior open bite.

A21

In this case, the bicuspid is the most anterior tooth.



Note that there are no green excursive marks made during lateral movements on any of the posterior teeth.

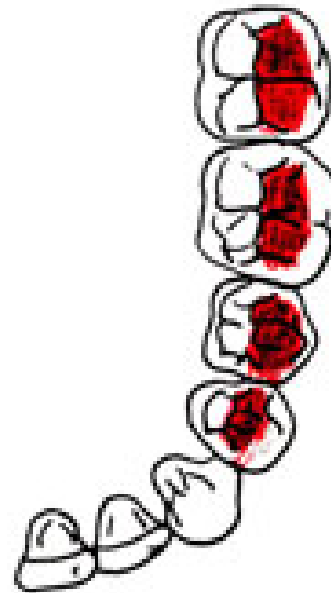
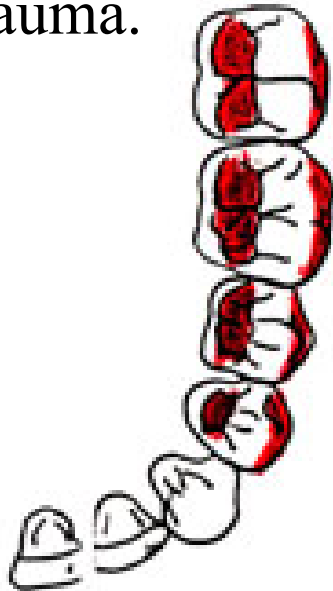
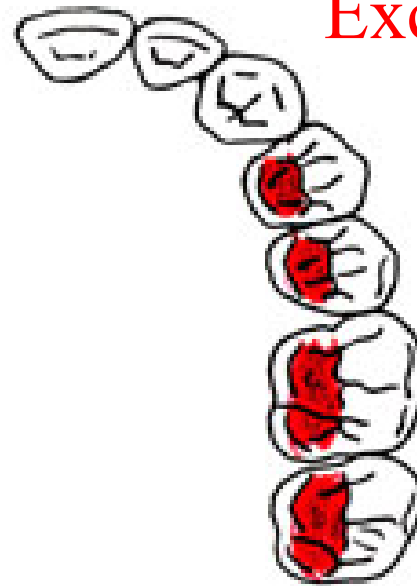
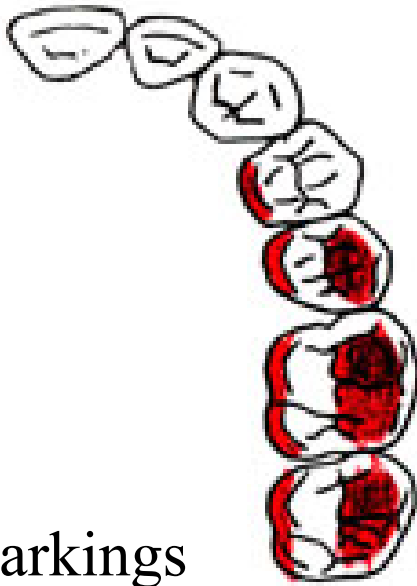
Correct excursive marks (green).

4. Disclusion of all the **posterior teeth** on the non-working or balancing side (side where the lower teeth are moving toward the tongue).

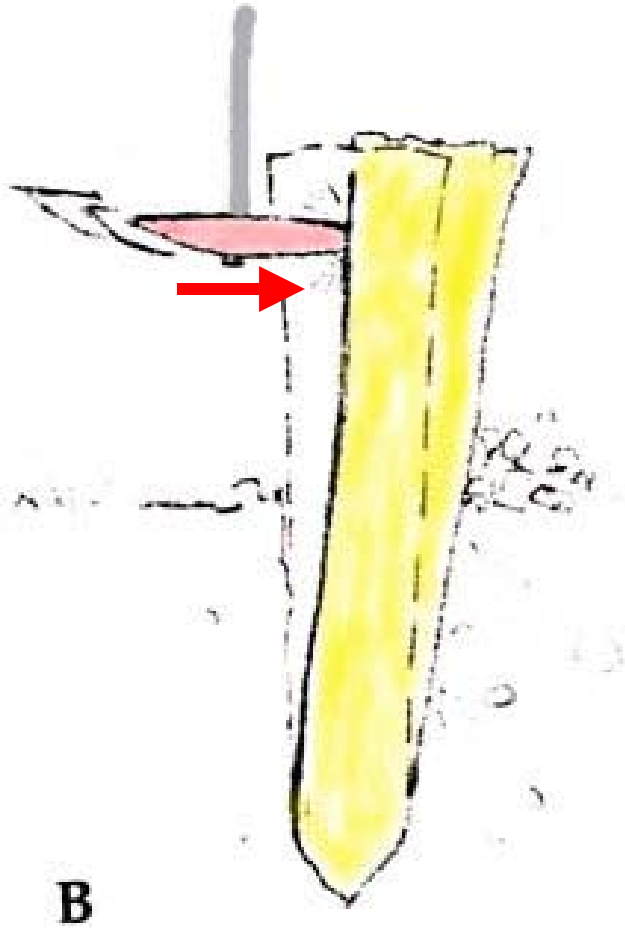
5. Disclusion of all the **posterior teeth** on the working side during excursions (side where the lower teeth are moving toward the cheek).

Excursive interferences

These markings
are indicators of
occlusal trauma.



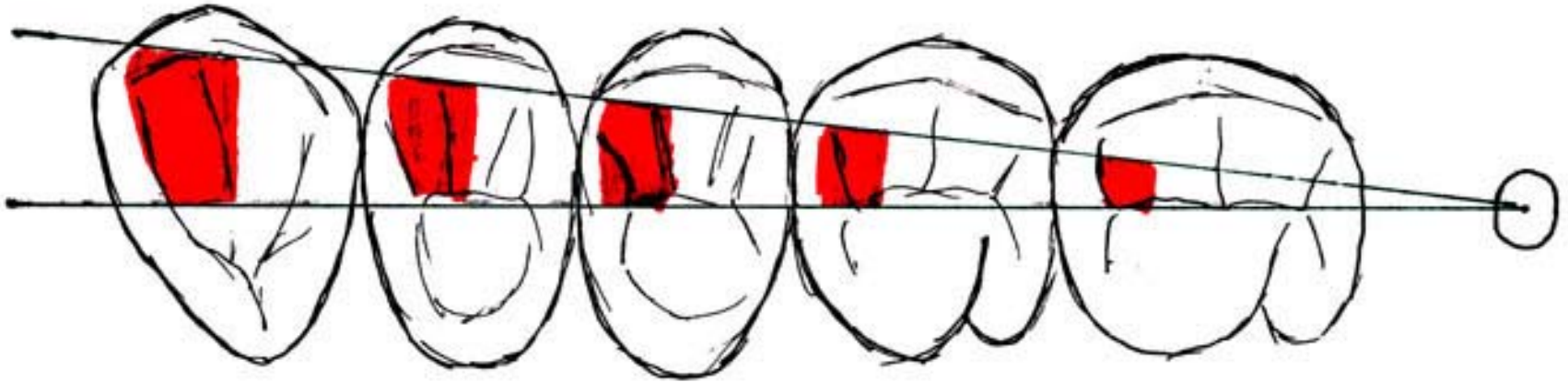
A light lateral force can loosen a post, just as it can loosen a tooth. It could also make a tooth sensitive.



Exception for rule 5.

- Teeth may be in **GROUP FUNCTION** if they are in precise harmony with anterior and condylar guidance.

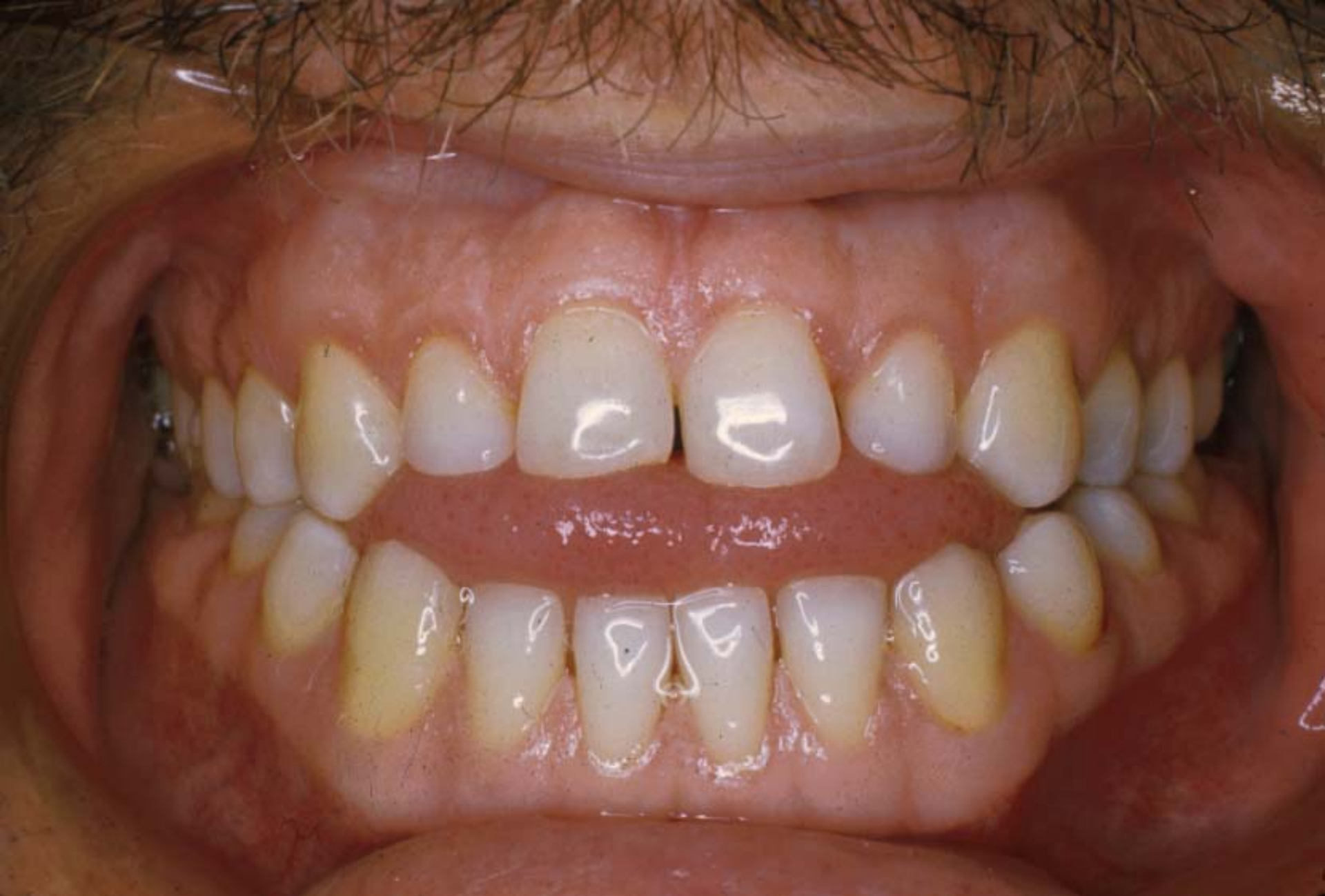Balanced working stroke.



Group function.

Other exception:

- The patient provides a substitute
 - i.e.- If a tongue thrust holds the teeth apart.

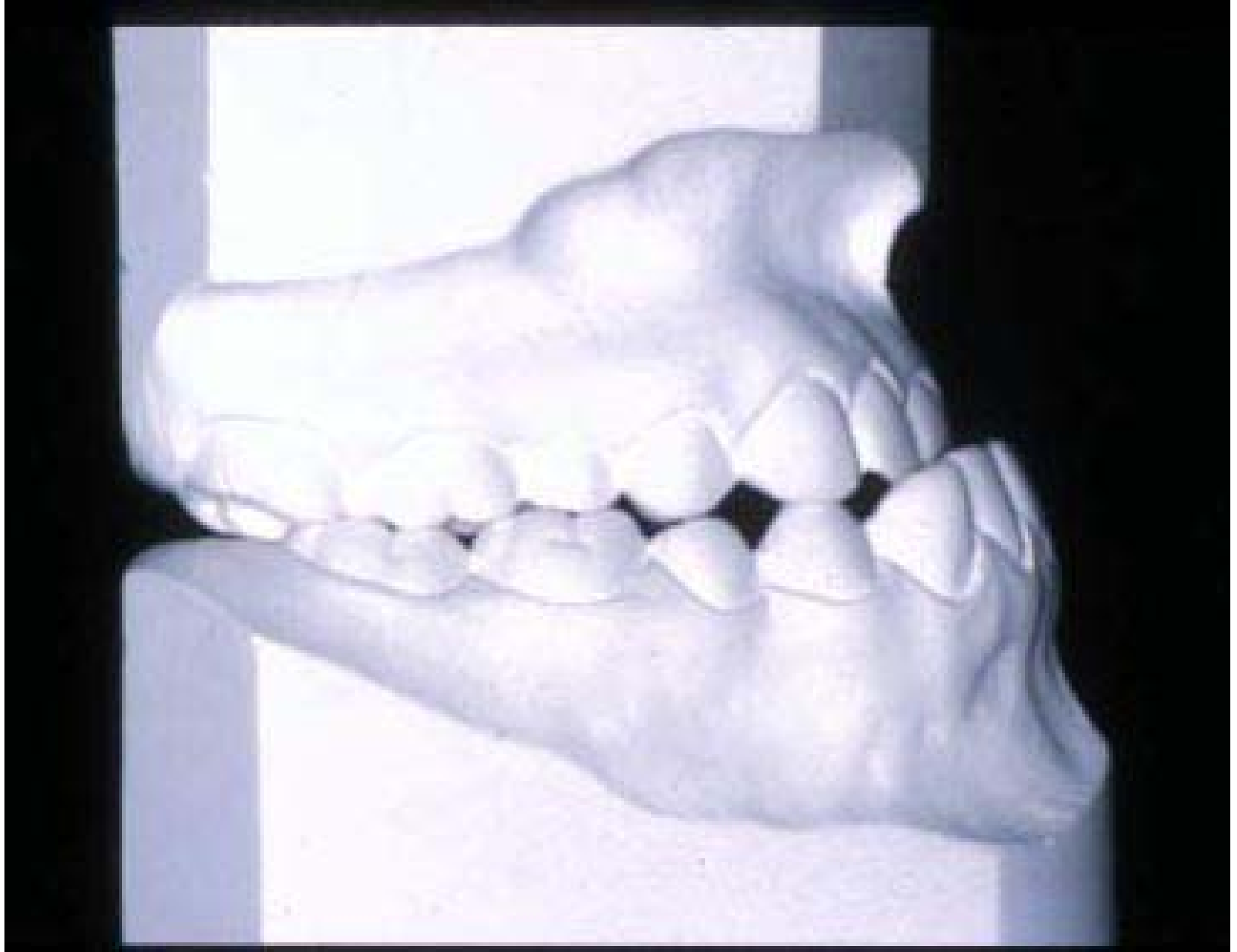


A30

An anterior tongue thrust.

Other exception:

- The patient eliminates the need:
 - i.e. – People with a Class III occlusion usually have a “chop-chop” bite and the mandible is already forward.



Class III malocclusion (Lateral view)

Key Points:

All five requirements must be fulfilled or one or more signs of instability will be seen in time.

- Teeth could loosen.
- Teeth could wear excessively.
- Teeth could move out of alignment.
- Teeth could get sore.
- Teeth could get cervical notching – abfractions.
- Open contact could develop.
- TMJ could break down.
- Bone loss could occur.
- Tori could develop.

Summary of article by Williamson and Lundquist:

“The elimination of posterior contacts by an appropriate anterior guidance reduces the elevating activity of the temporal muscles.”

Williamson EH.,Lundquist DO., Anterior guidance: its effect on electromyographic activity of the temporal and masseter muscles. J. Prosthetic Dentistry.49(6):816-23, 1983 June.

Curve of Spee:

Allows for the normal functional protrusive movement of the mandible.

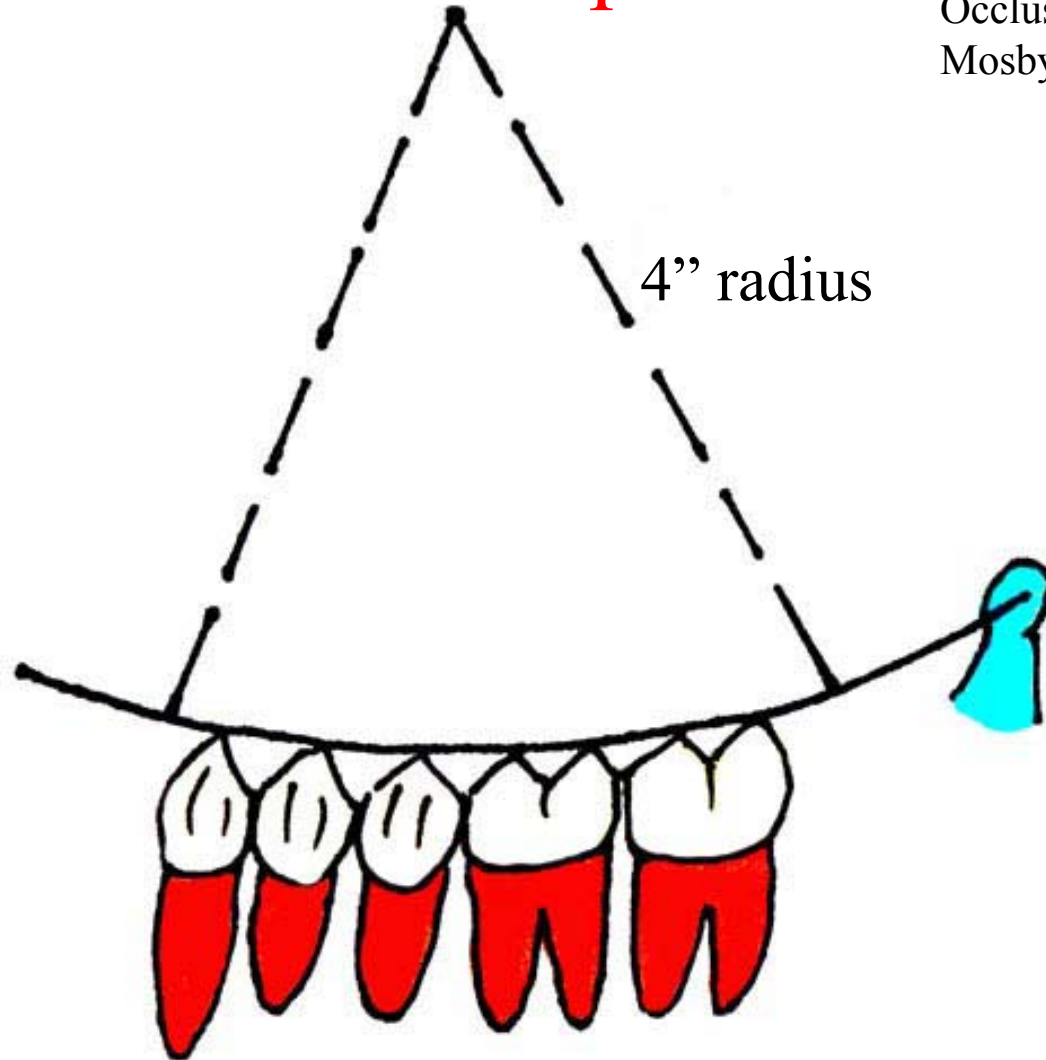
Curve of Wilson:

Allows for those exquisite movements which are used in chewing functions..

Peter E. Dawson. Evaluation, Diagnosis, and Treatment of Occlusal Problems, 2nd ed.. Mosby.

Curve of Spee.

Peter E. Dawson. Evaluation, Diagnosis, and Treatment of Occlusal Problems, 2nd ed.. Mosby. P85.



Anteroposterior curvature of the occlusal surfaces.

Curve of Spee

The curve of Spee begins at the tip of the lower cuspid and touches the buccal cusp tips of all the mandibular posterior teeth and continues to the anterior border of the ramus. (p85)

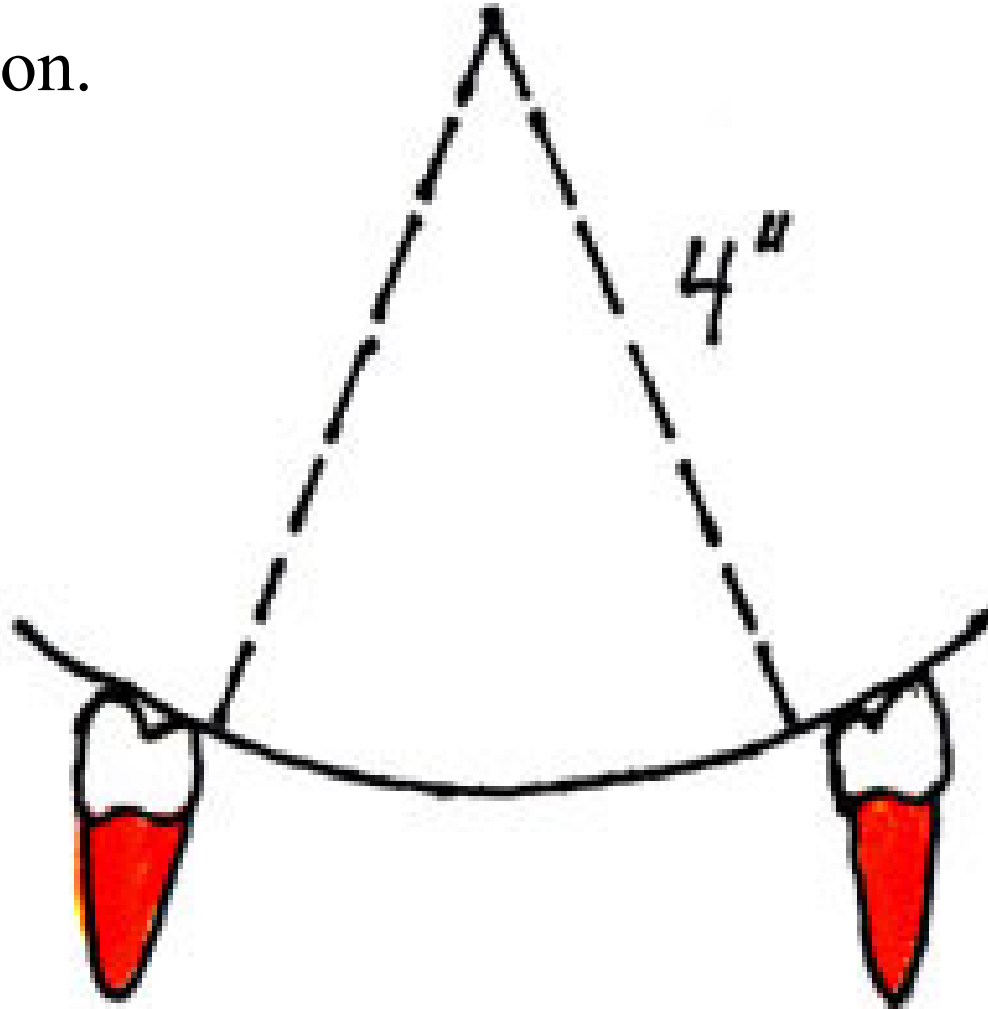
An ideal curve of Spee is aligned so that a continuation of this arc would extend through the condyles.

The curvature of this arc would relate, on average, to part of a circle with a 4-inch radius.

A37

Buccal - Lingual Curvature.

For mastication.



Curve of Wilson.

Curve of Wilson.

The curve of Wilson is the mediolateral curve that contacts the buccal and lingual cusp tips of each side of the arch. It results from the inward inclination of the lower posterior teeth, making the lingual cusps lower than the buccal cups on the mandibular arch; the buccal cusps are higher than the lingual cusps on the maxillary arch because of the outward inclination of the upper posterior teeth.

Peter E. Dawson. Evaluation, Diagnosis, and Treatment of Occlusal Problems, 2nd ed.. Mosby. P88.

Curve of Wilson. Impact on chewing.

The lingual inclination of the lower posterior teeth positions the lingual cusps lower than the buccal cusps. This design permits easy access to the occlusal table. As the tongue lays the food on the occlusal surfaces, it is stopped from going past the chewing position by the taller buccal cusps.

Peter E. Dawson. Evaluation, Diagnosis, and Treatment of Occlusal Problems, 2nd ed.. Mosby. P89.



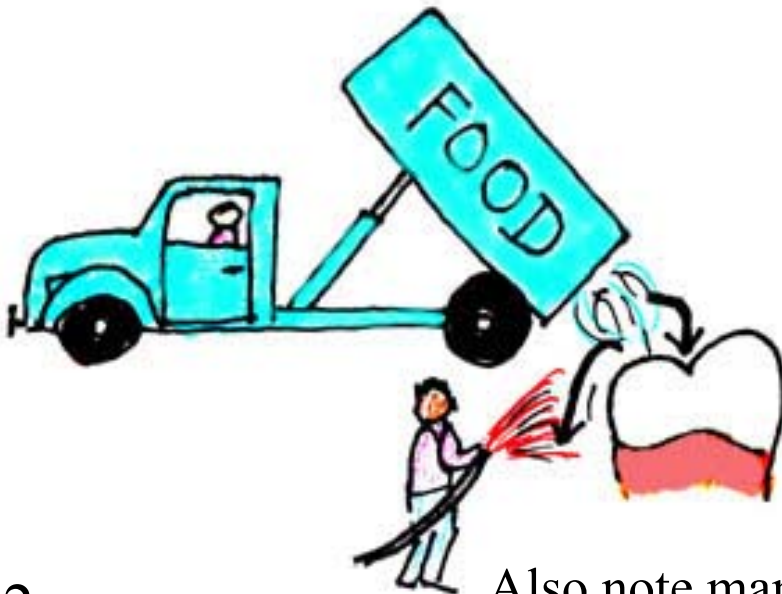One of the **functions of our tongue:**

Dump food into our mouth.

Functions of the tongue.



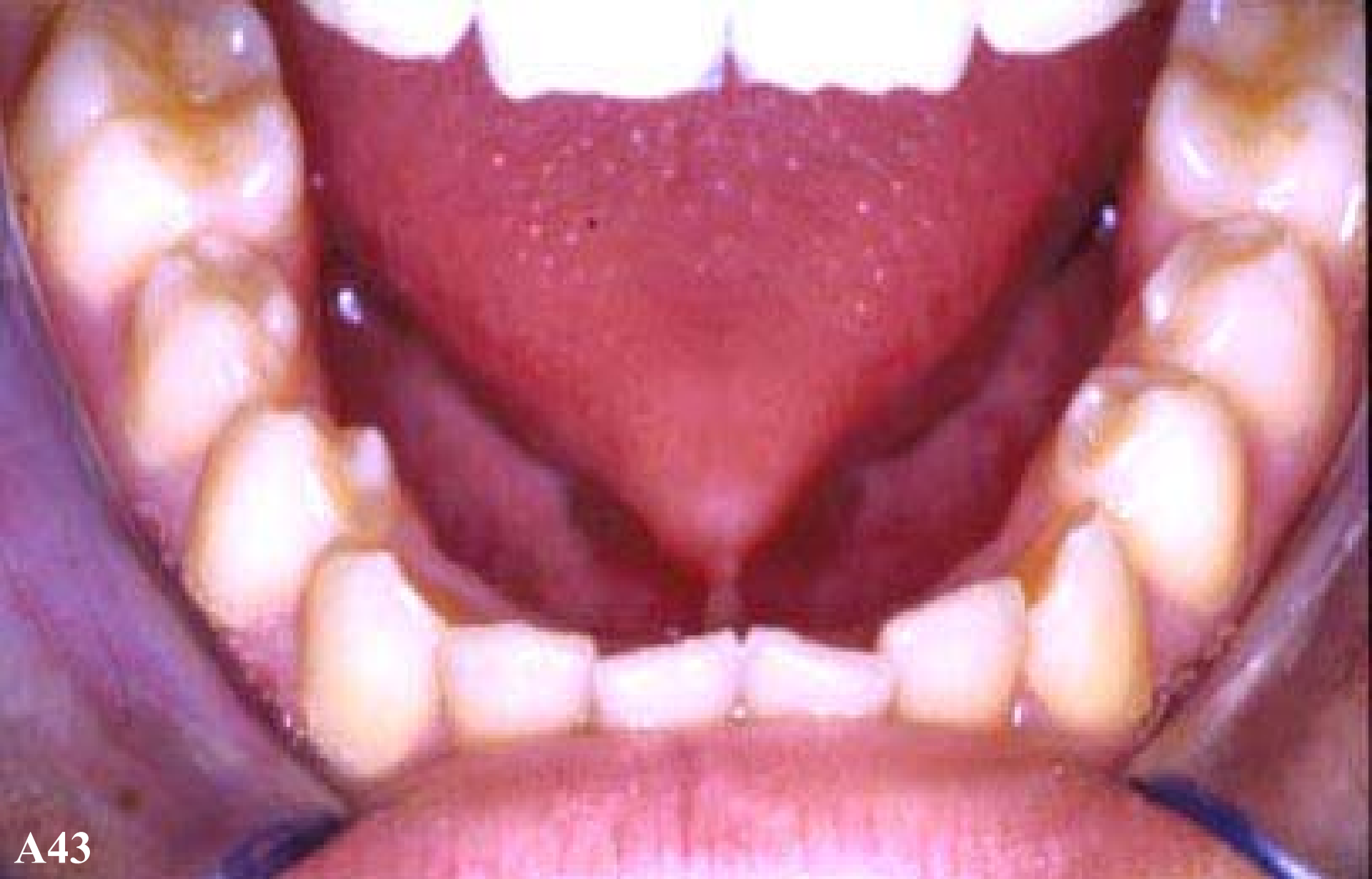Dumps food down our throat after having 'mashed' the food against our palate during mastication.



Dumps food laterally onto our teeth during mastication.

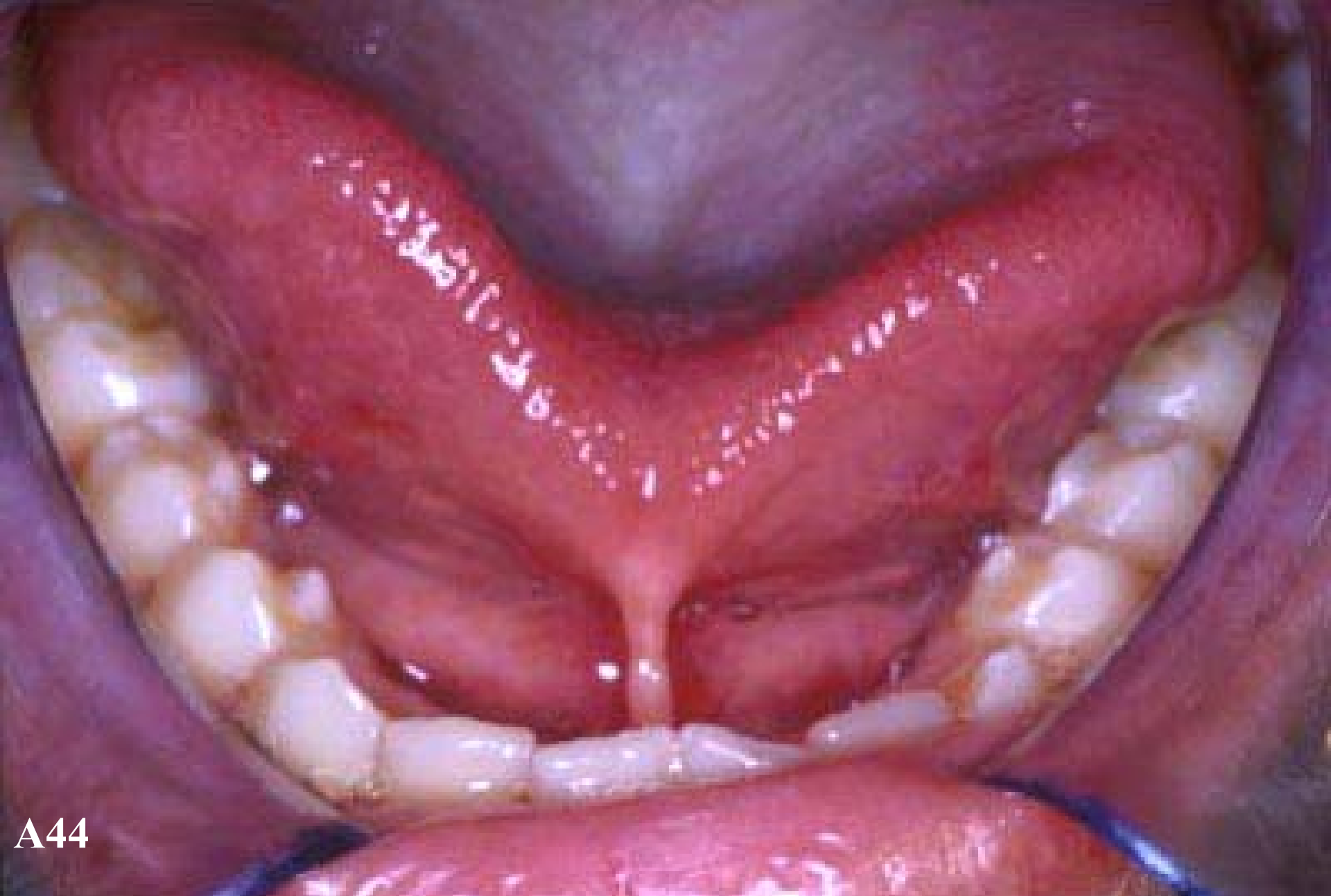Note importance of **curve of Wilson** here.

Also note man squirting digestive enzymes onto the food.



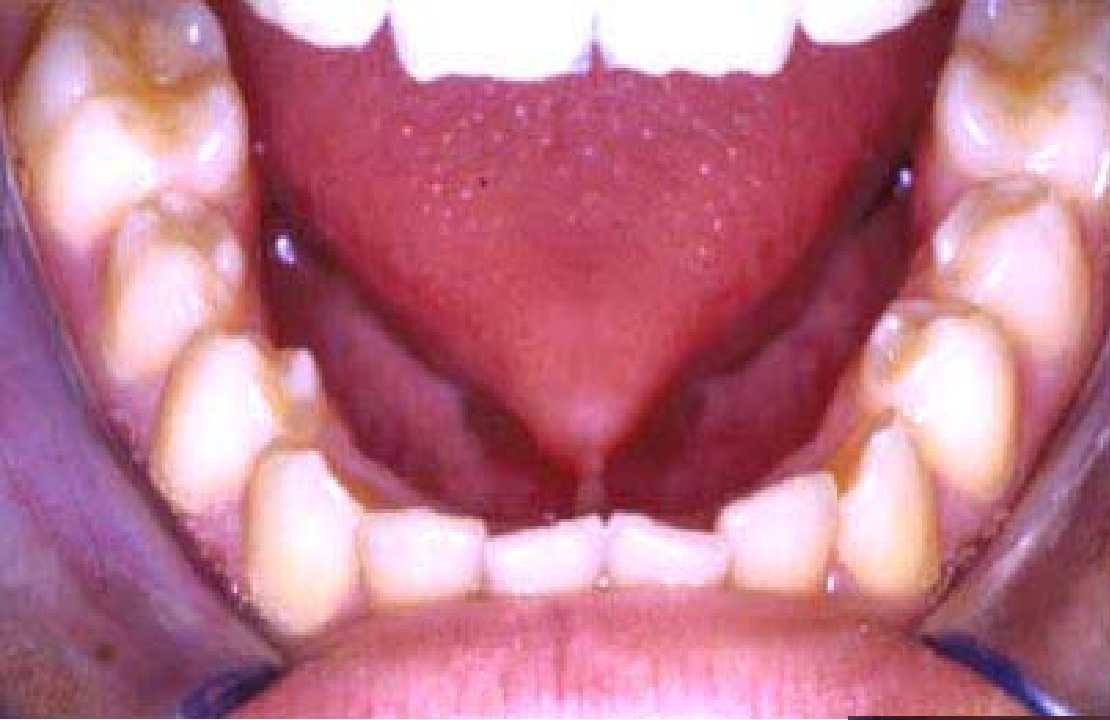A43

A 13 year-old who is severely tongue-tied. He has stomach pains, irregular stools and trouble saying some words.



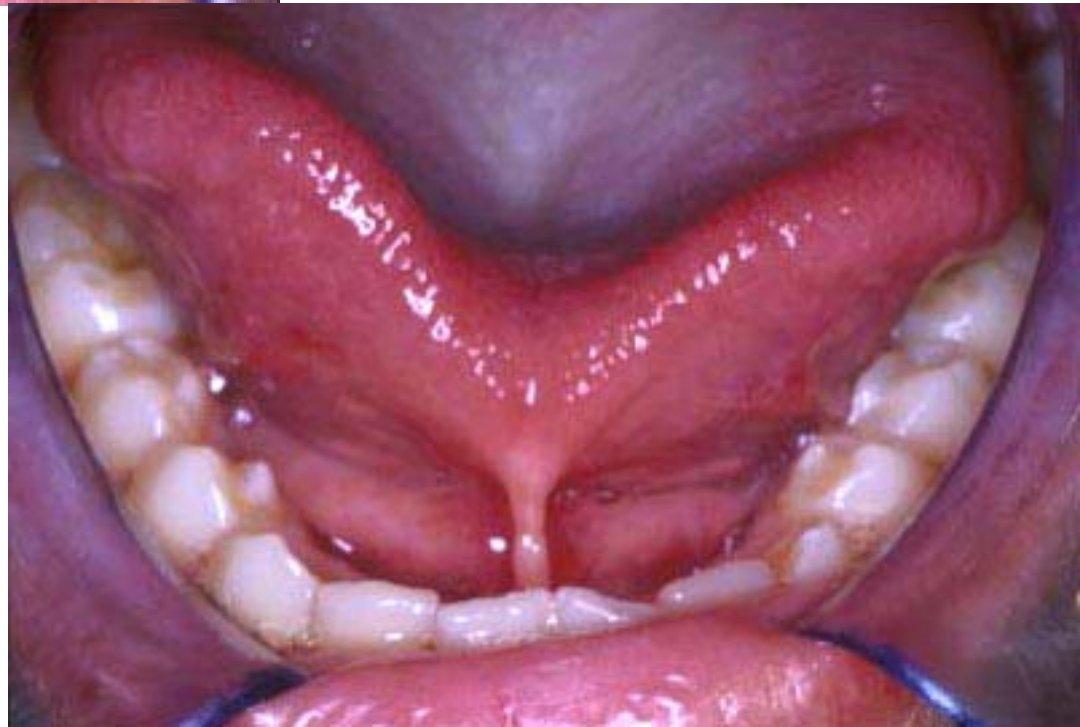A44

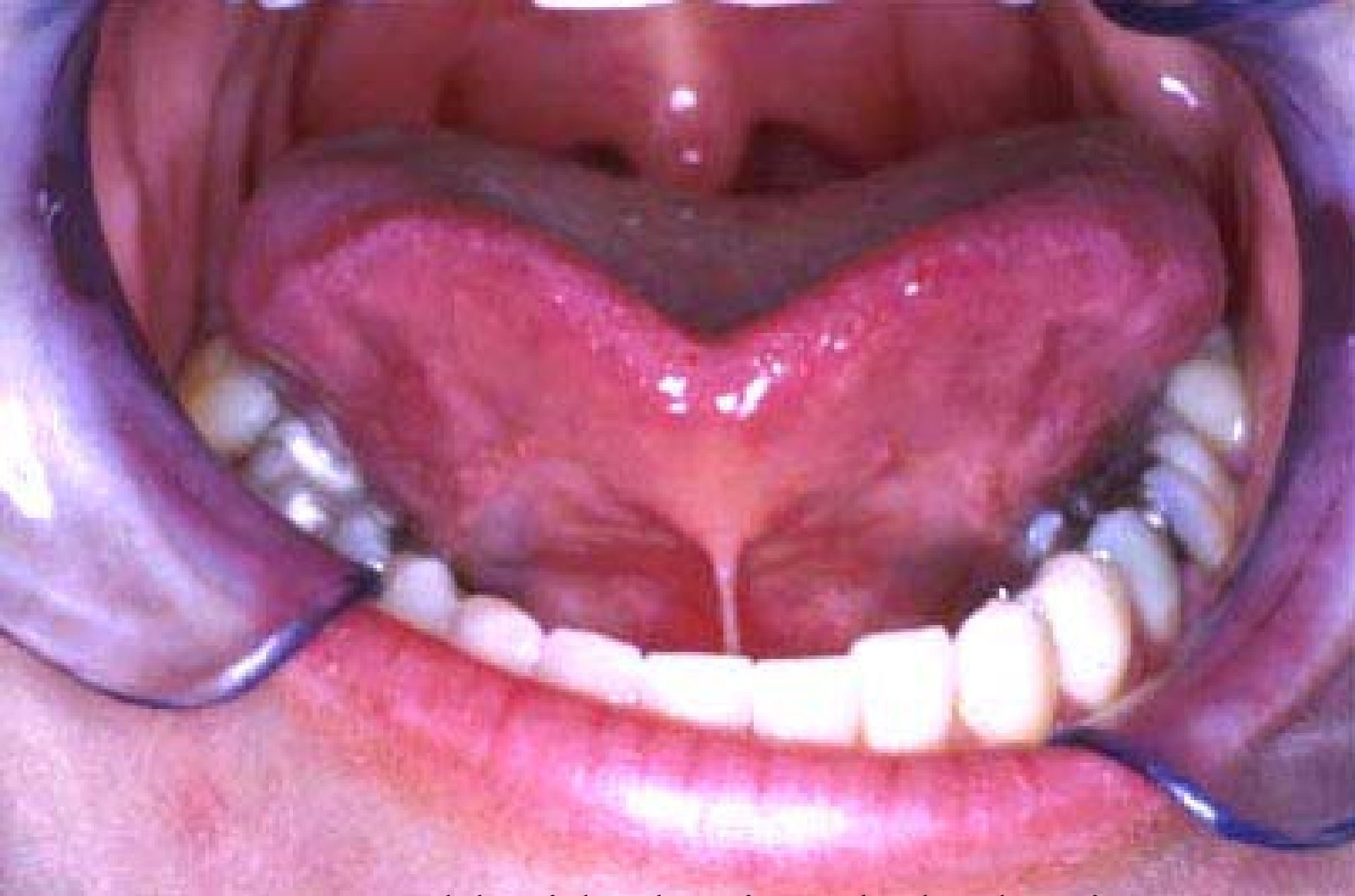He has trouble directing food for proper chewing and swallowing.
Would have difficulty mashing food against his palate.



Tight frenum limits elevation of tongue in this 13-year-old boy.

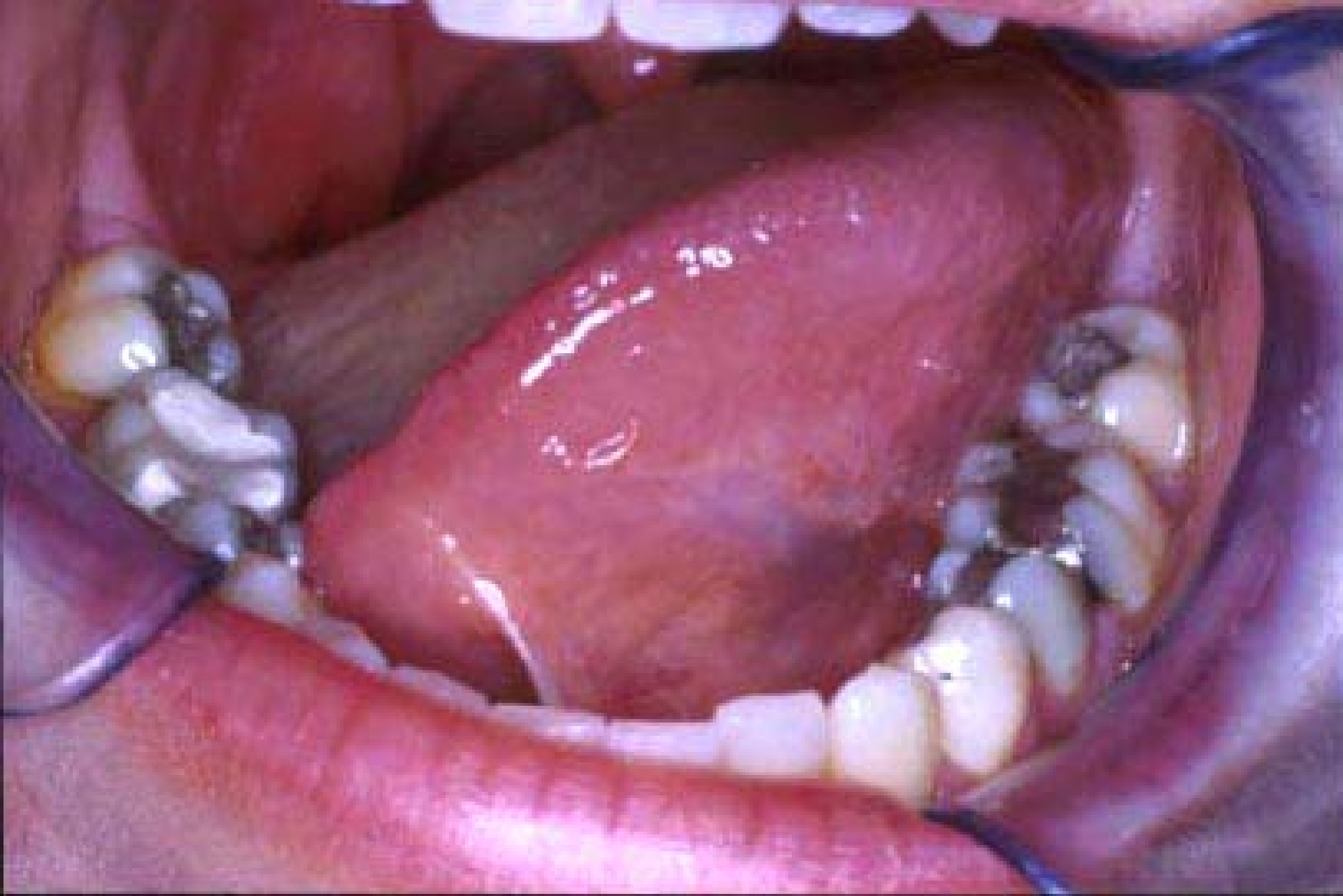Tight frenum makes 'mashing of food' against palate difficult, plus impacts ability to enunciate.





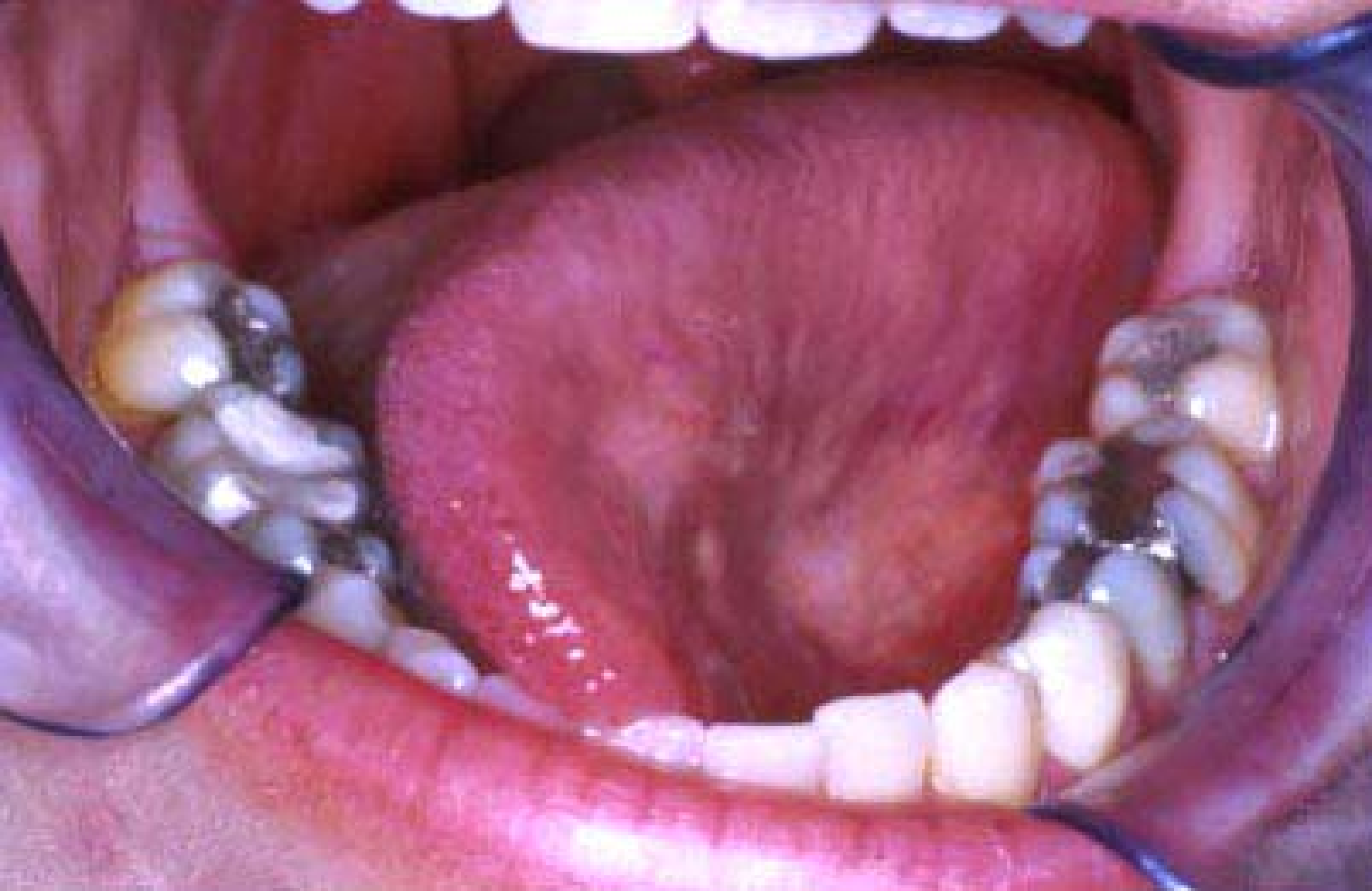26-year-old with classic ankyloglossia.

She has digestive problems as well.



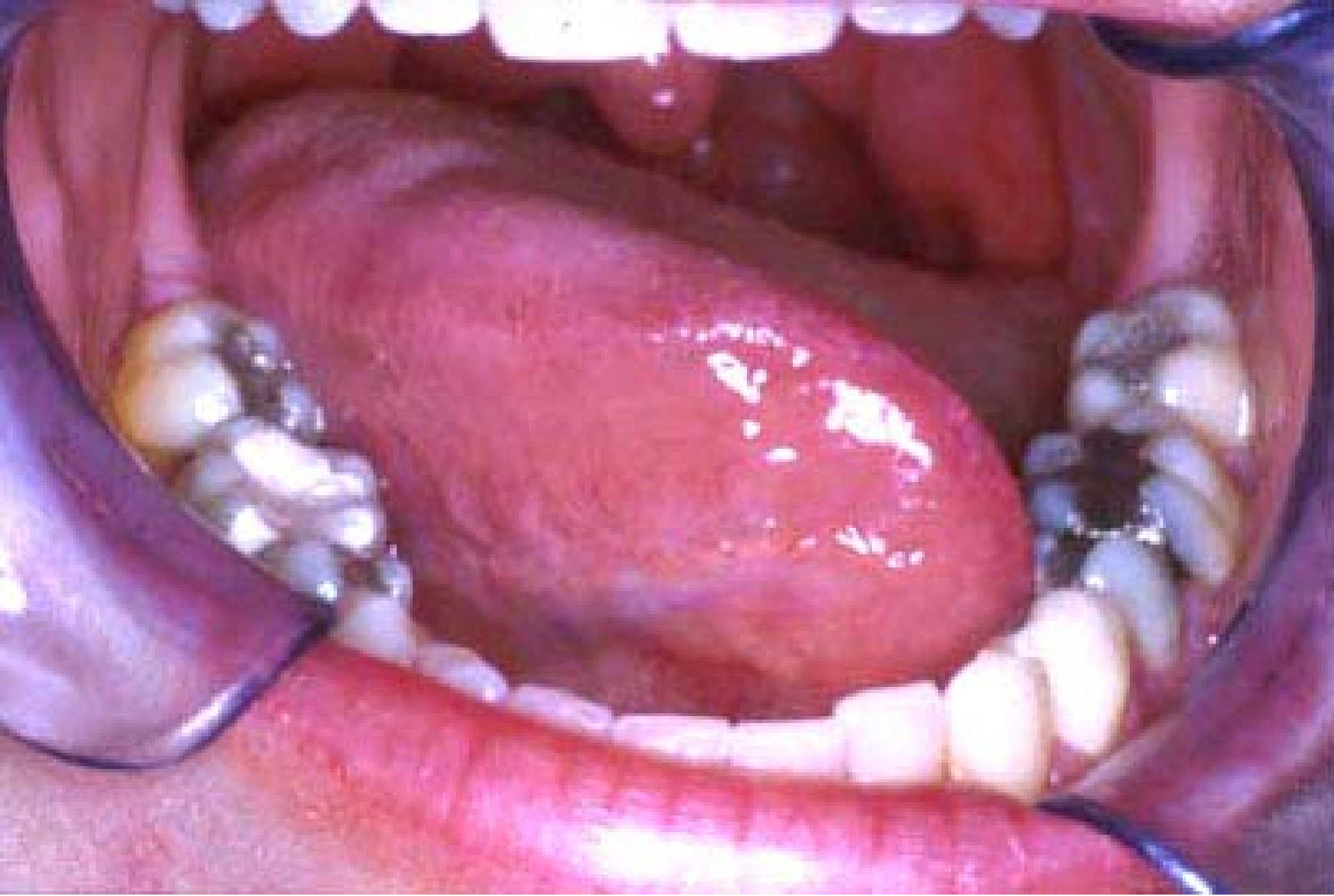A47

Restricted lateral movement. Age 26.



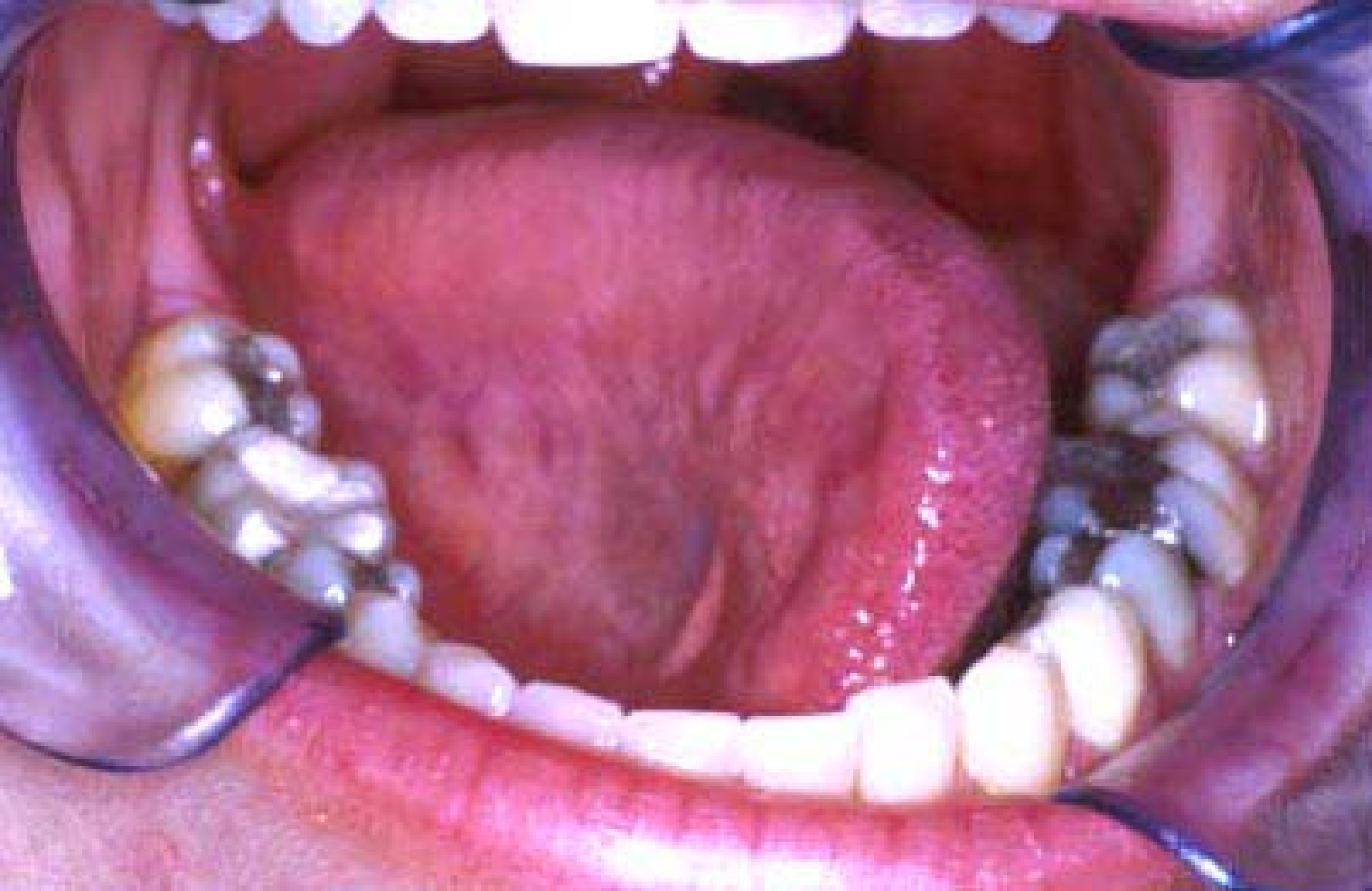Ineffective dumping of food onto teeth due to restricted lateral movement of tongue.

A48



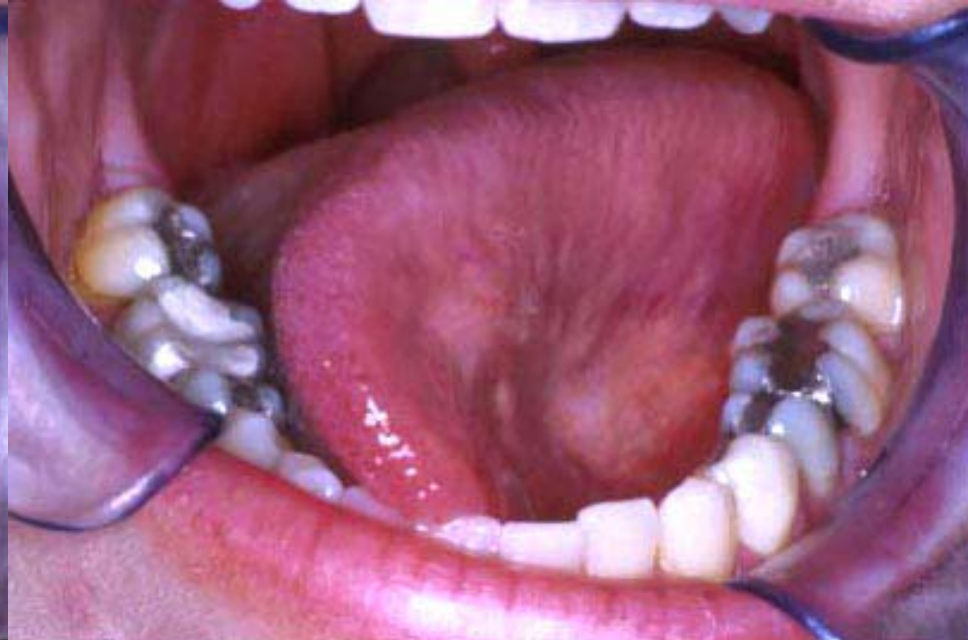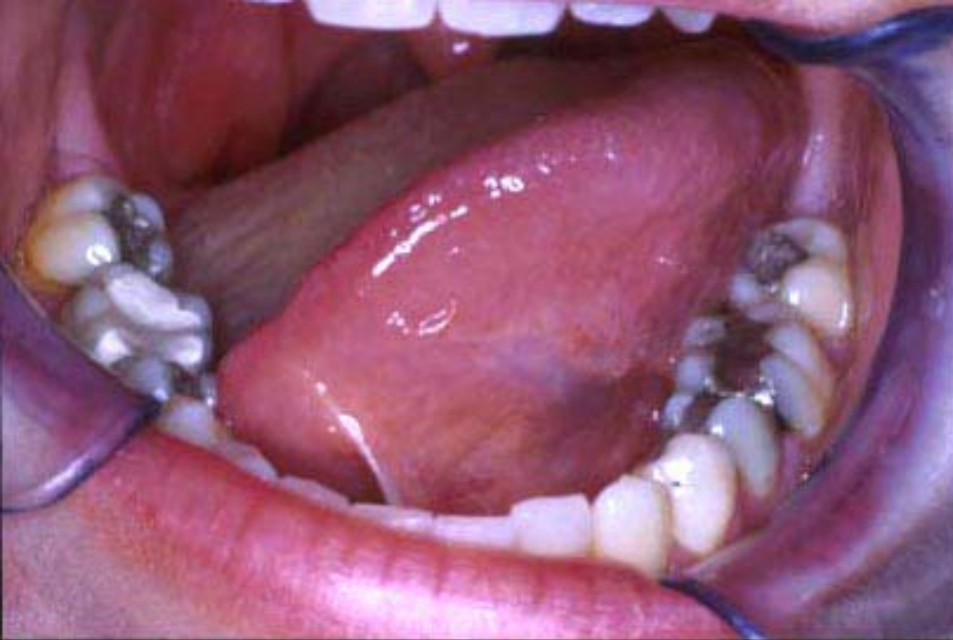A49

Restricted lateral movement. Age 26.

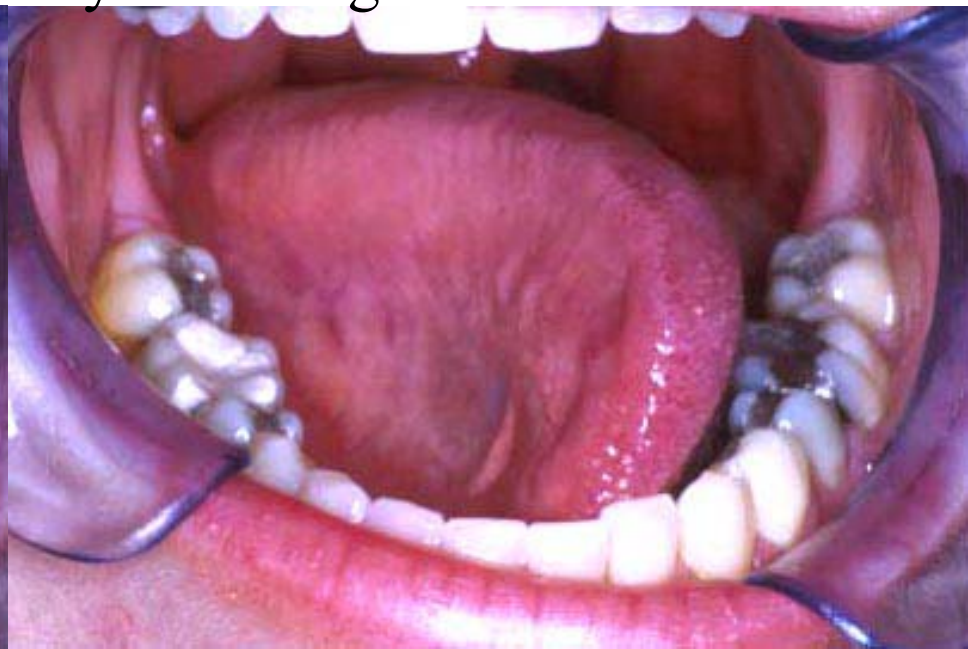
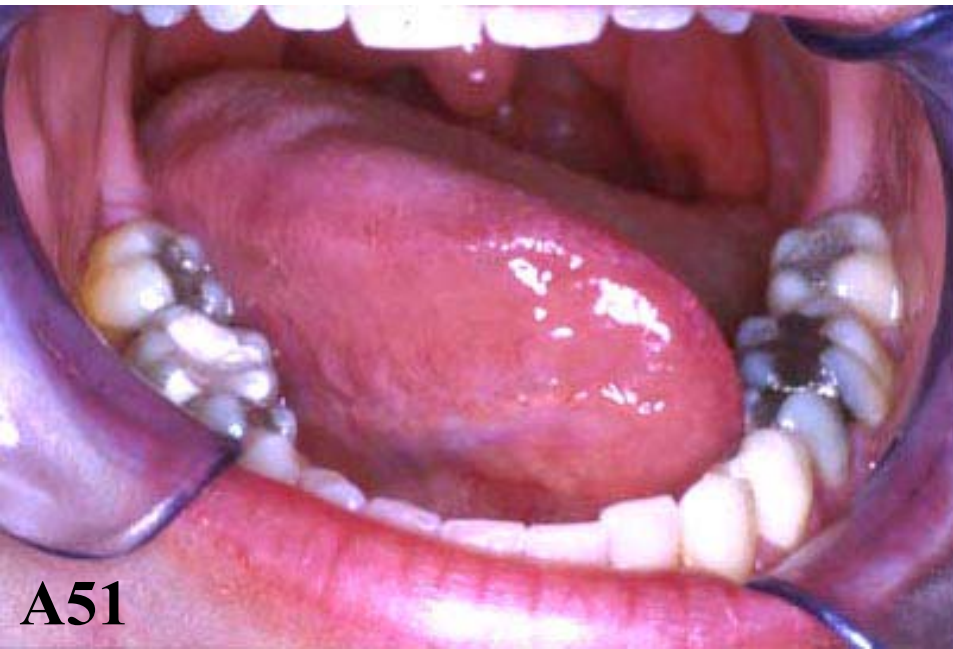
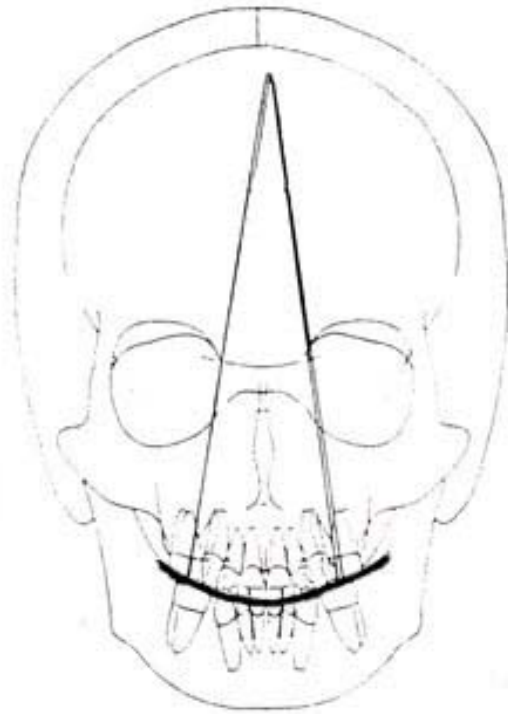
Ineffective dumping of food onto teeth due to restricted lateral movement of tongue.

A50

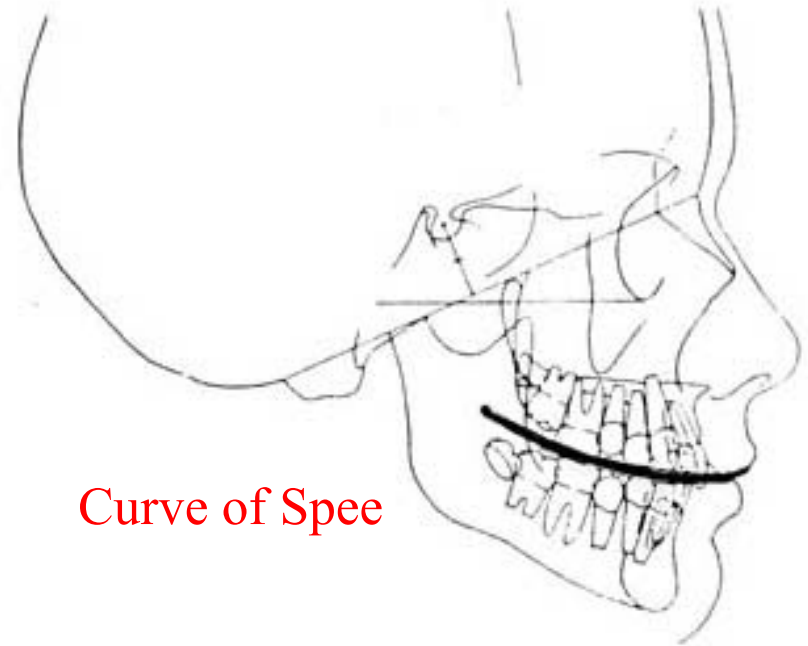


Beautiful illustration demonstrating limited movement of an ankylosed tongue.

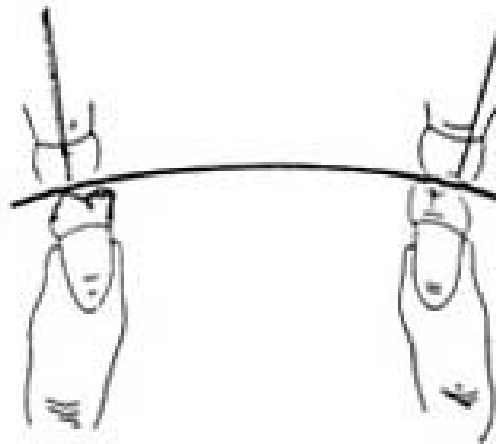




Curve of Wilson

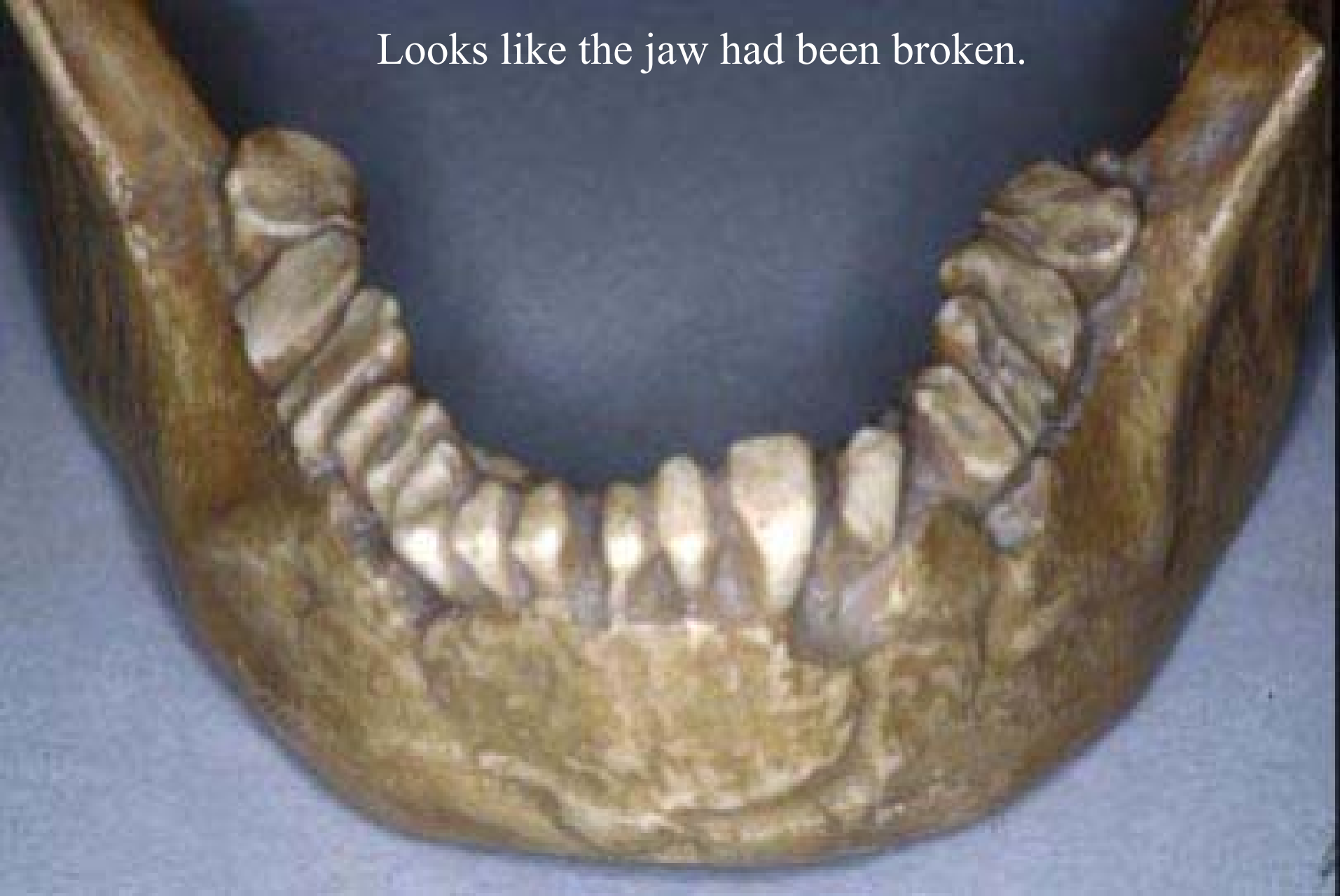


Curve of Spee




Reverse Curve of Wilson

Looks like the jaw had been broken.



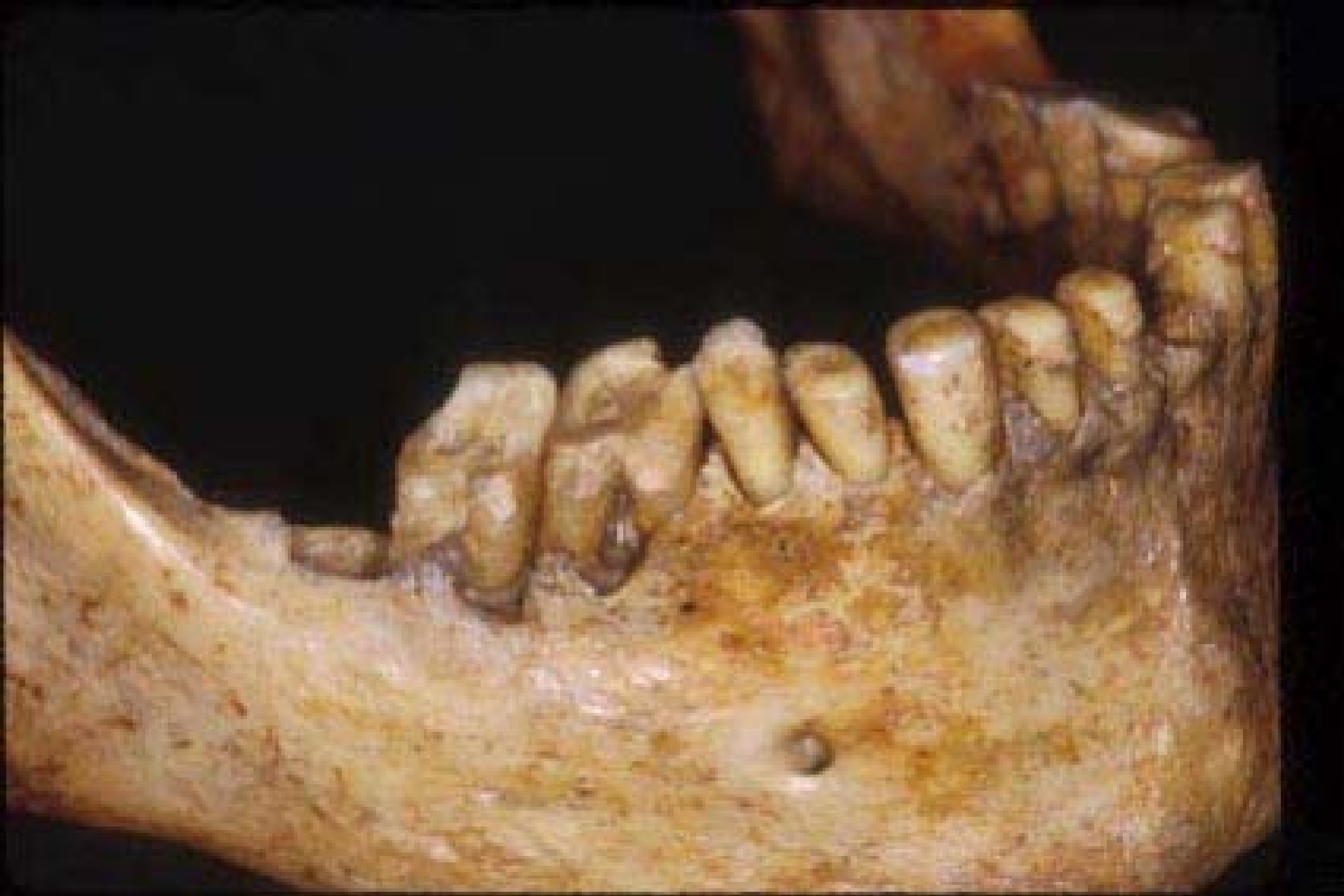A53 A prehistoric skull with a reverse curve of Wilson.



See next 3 slides.

Another skull with a reverse curve of Wilson.

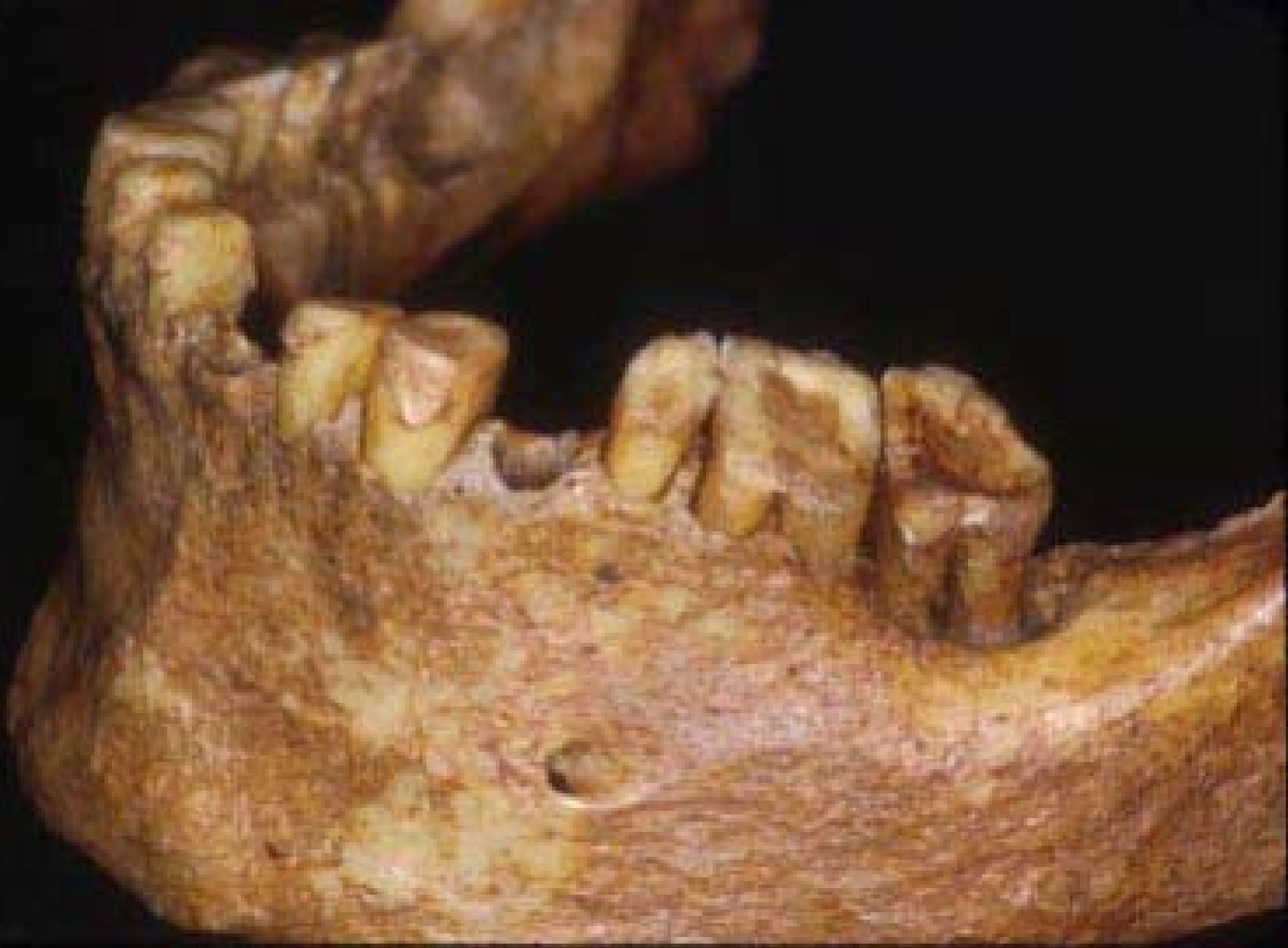A54



A55

Close up of same skull - right side.

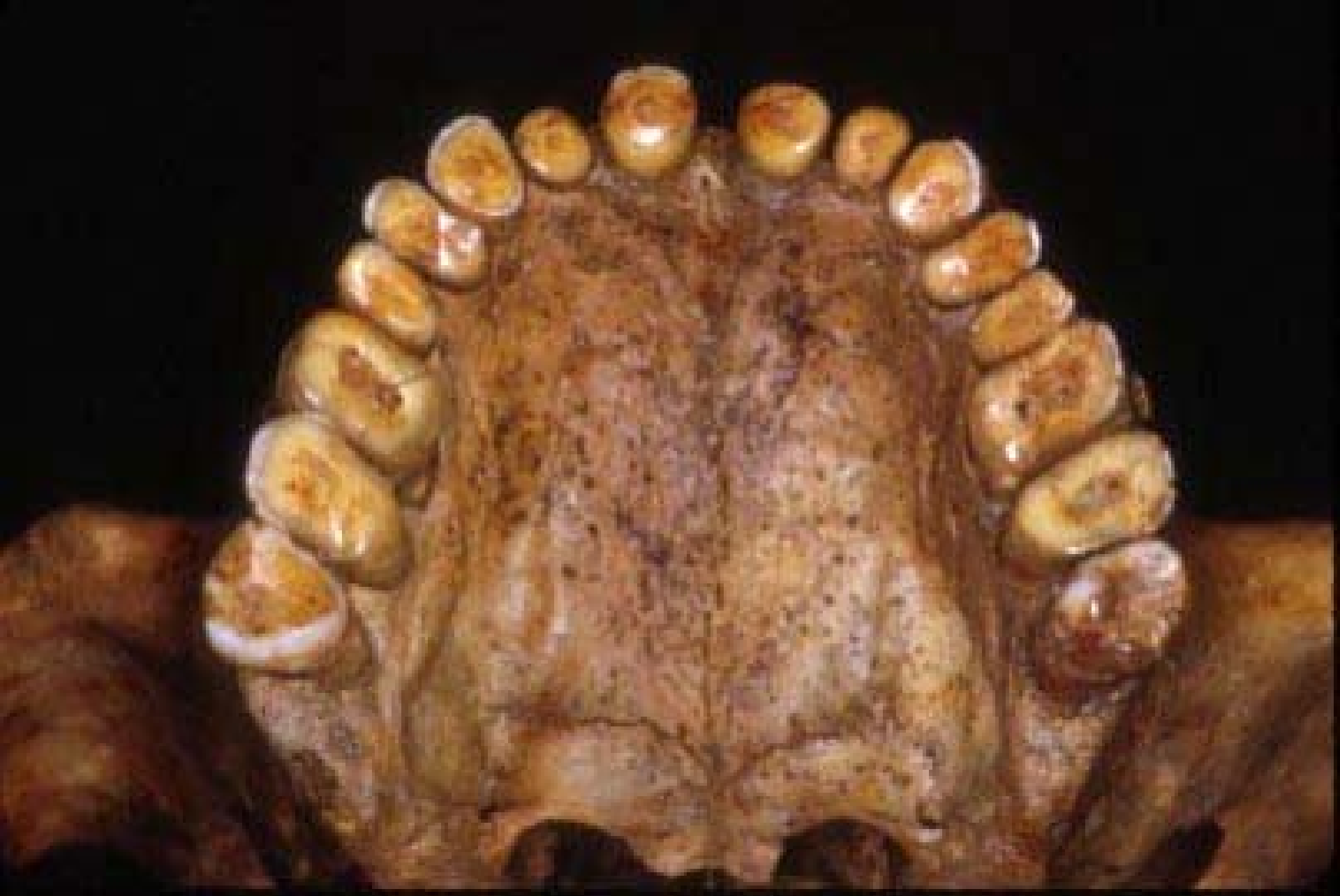
See next 2 slides.



A56

Close up of same skull - left side.

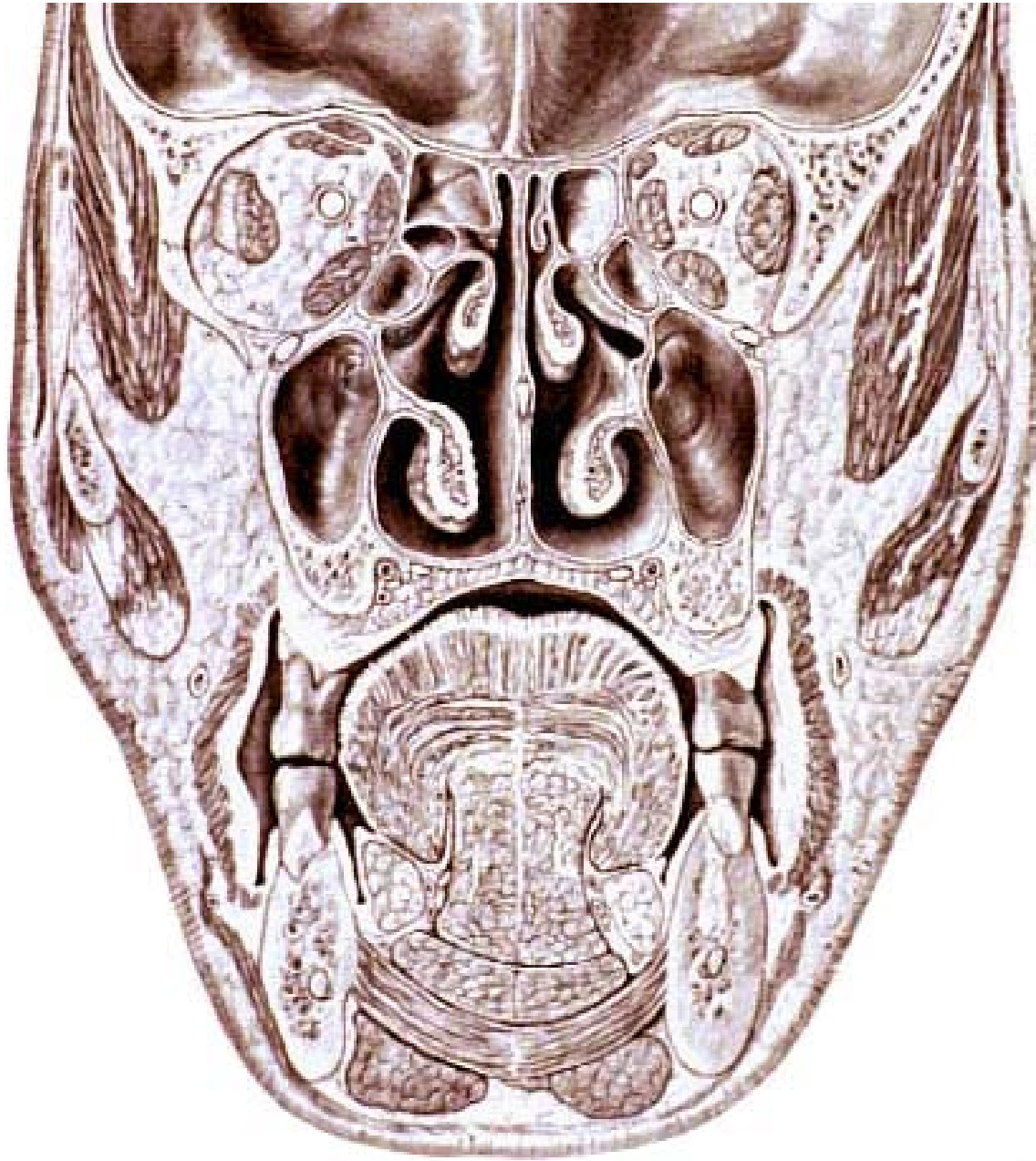
See next slide.



A57

Maxillary arch of same skull.

The 'Neutral Zone'

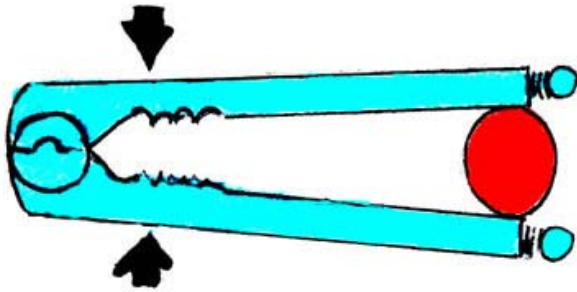


Tongue, teeth and cheeks are at rest in a “neutral” position. There are no abnormal forces within the mouth. This allows for the proper alignment of the teeth and dental arches.

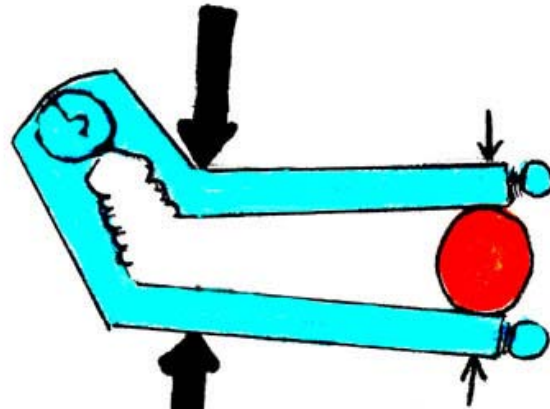
This also allows for normal facial development.

The jaw is like a nutcracker.

- Strongest muscle forces are exerted close to the hinge.
- The force diminishes as the distance from the fulcrum increases.
- Strong anterior stops protect the posterior teeth.

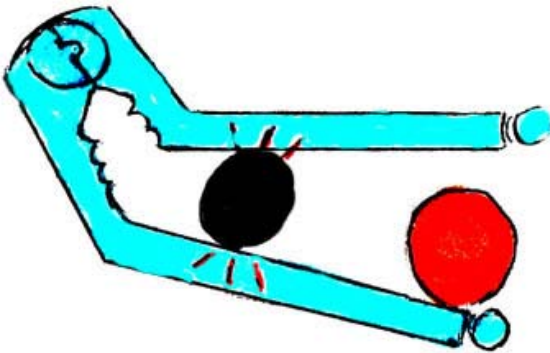


A

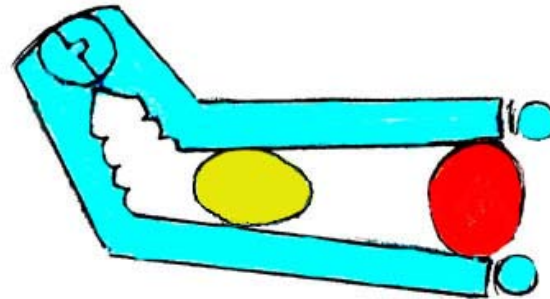


B

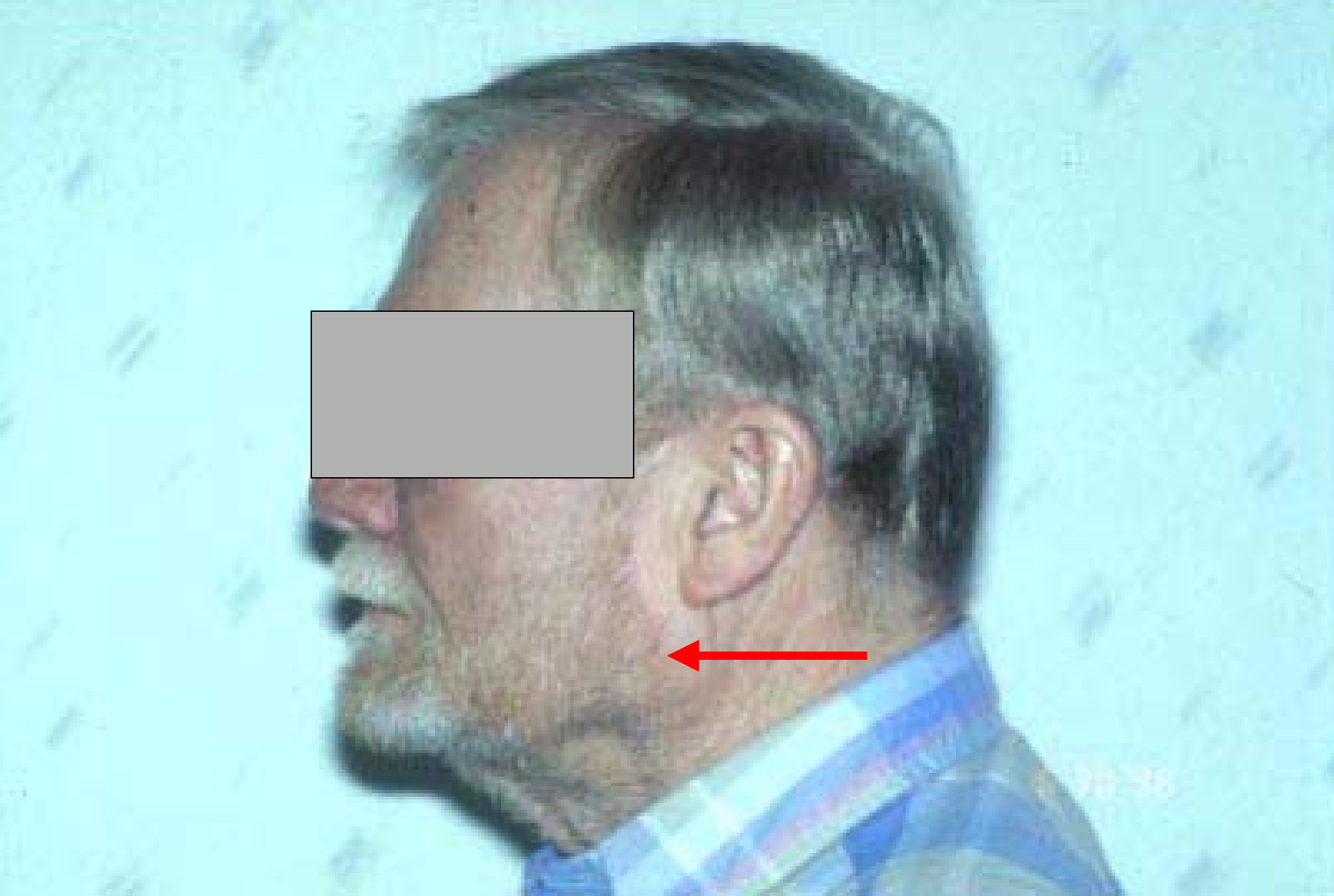Jaw as a nutcracker.



C

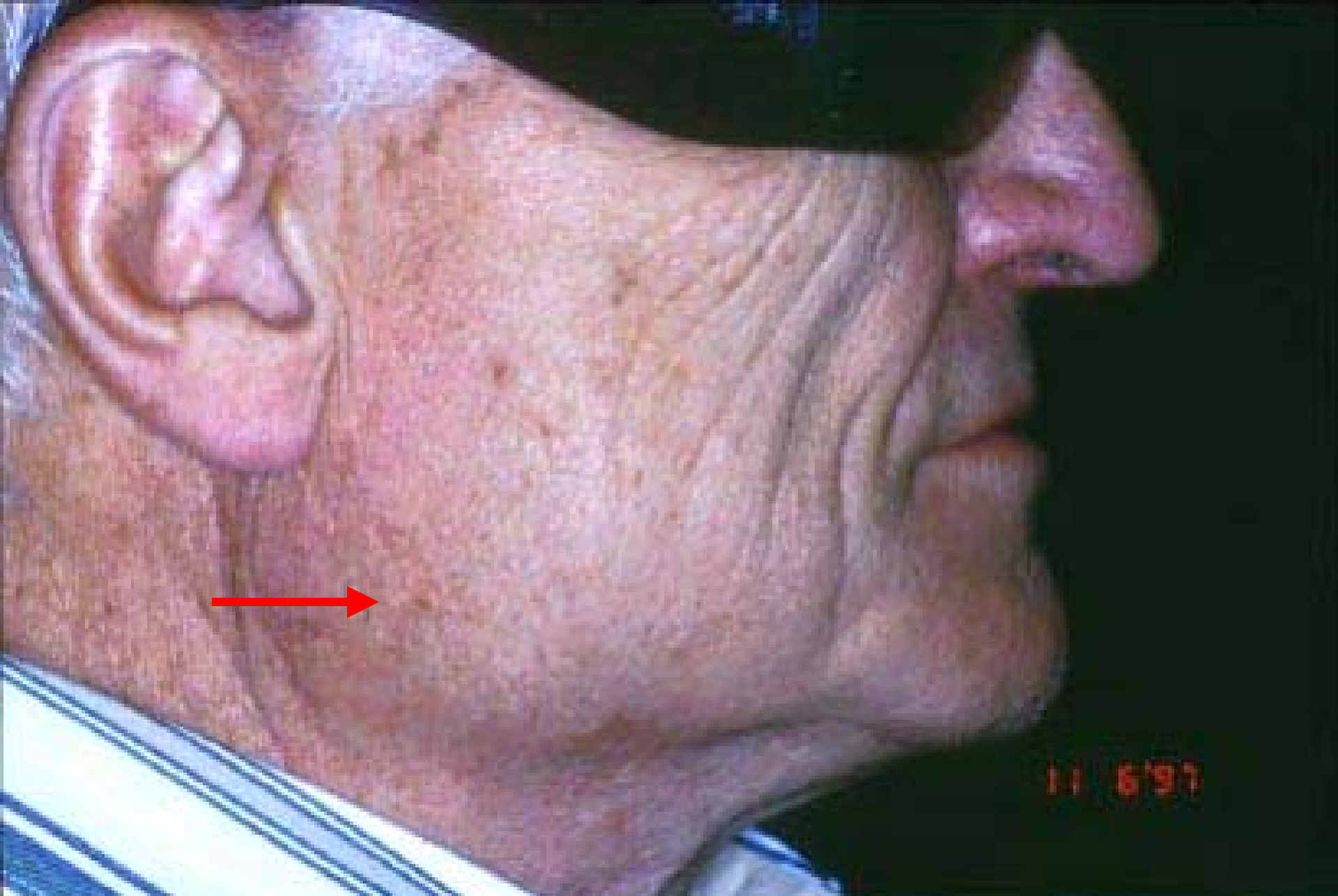


D



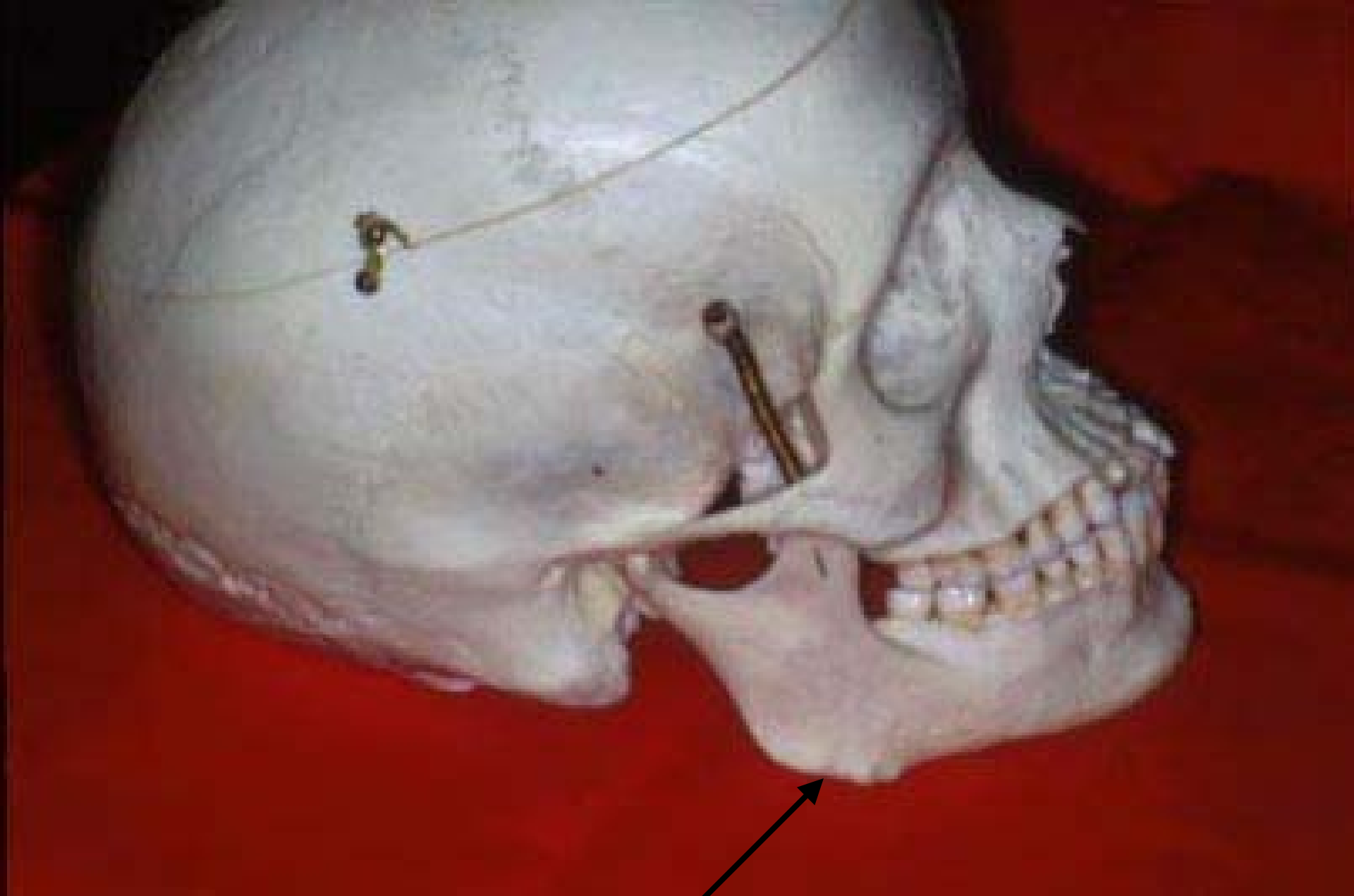
A62

Square jaw demonstrating strong masseters.



A63

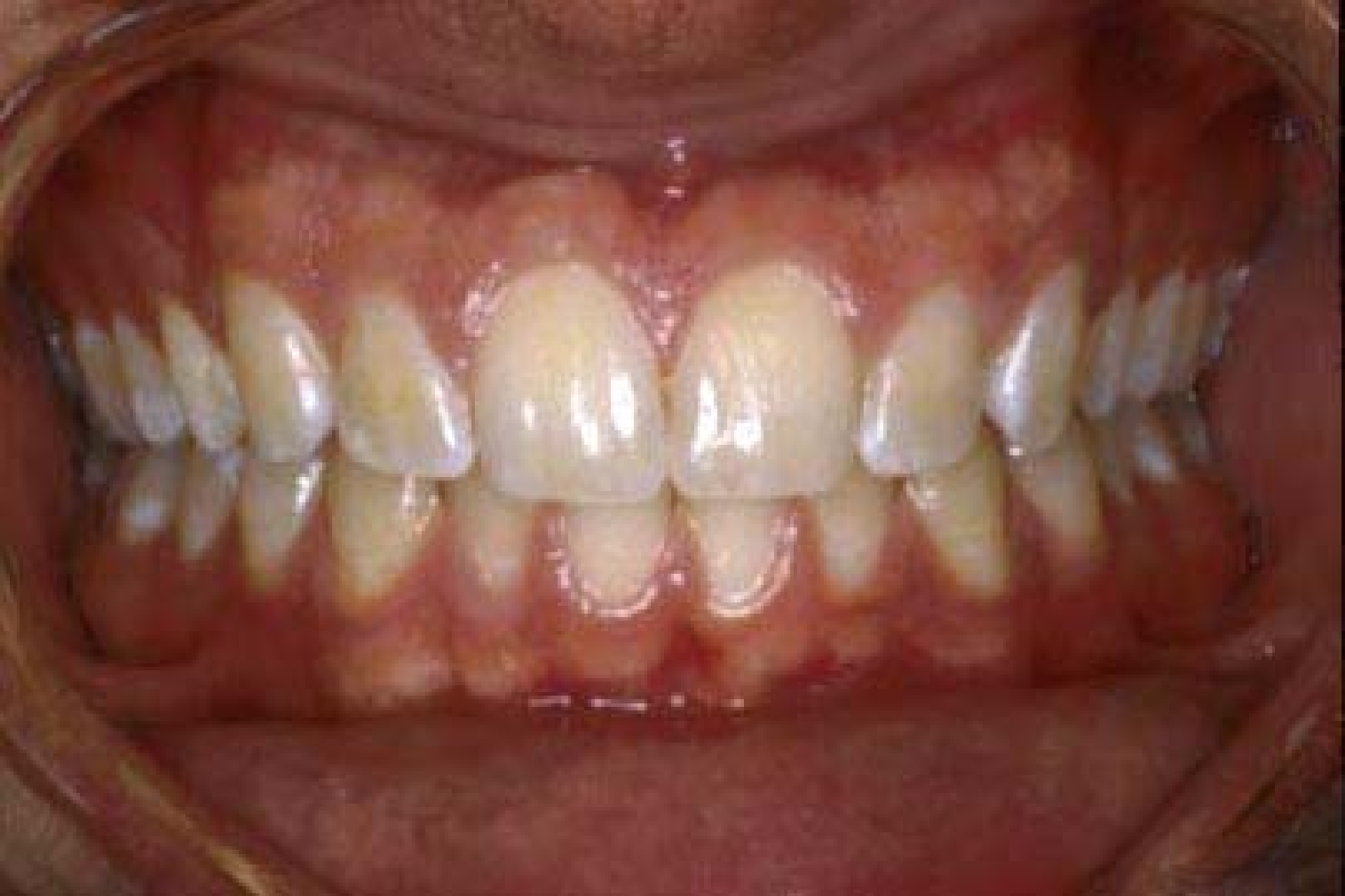Square jaw demonstrating strong masseters.



A64 Strong muscle attachment stimulated bone development.

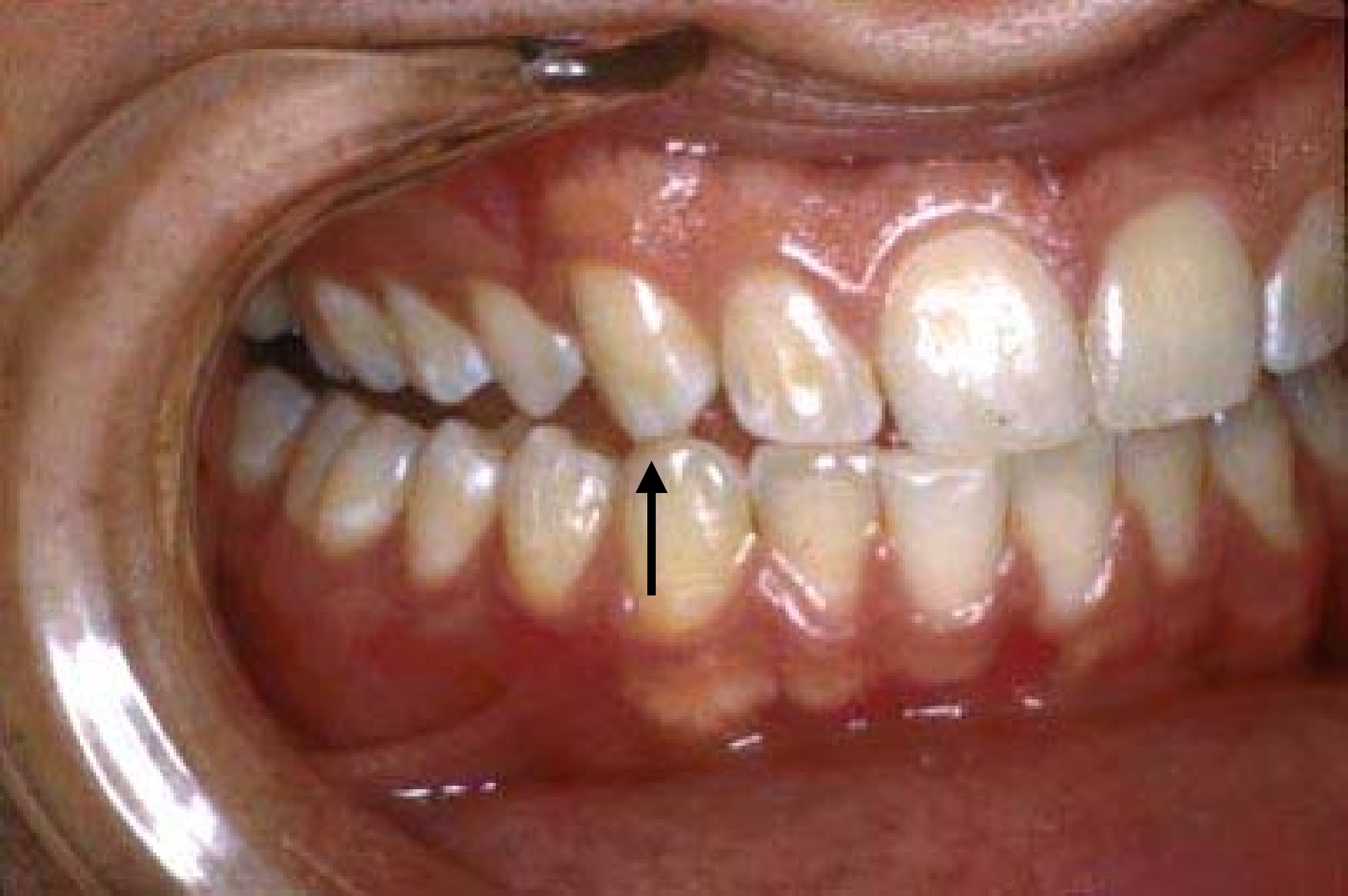Important Dental Concept

Cuspid Rise / Anterior Guidance

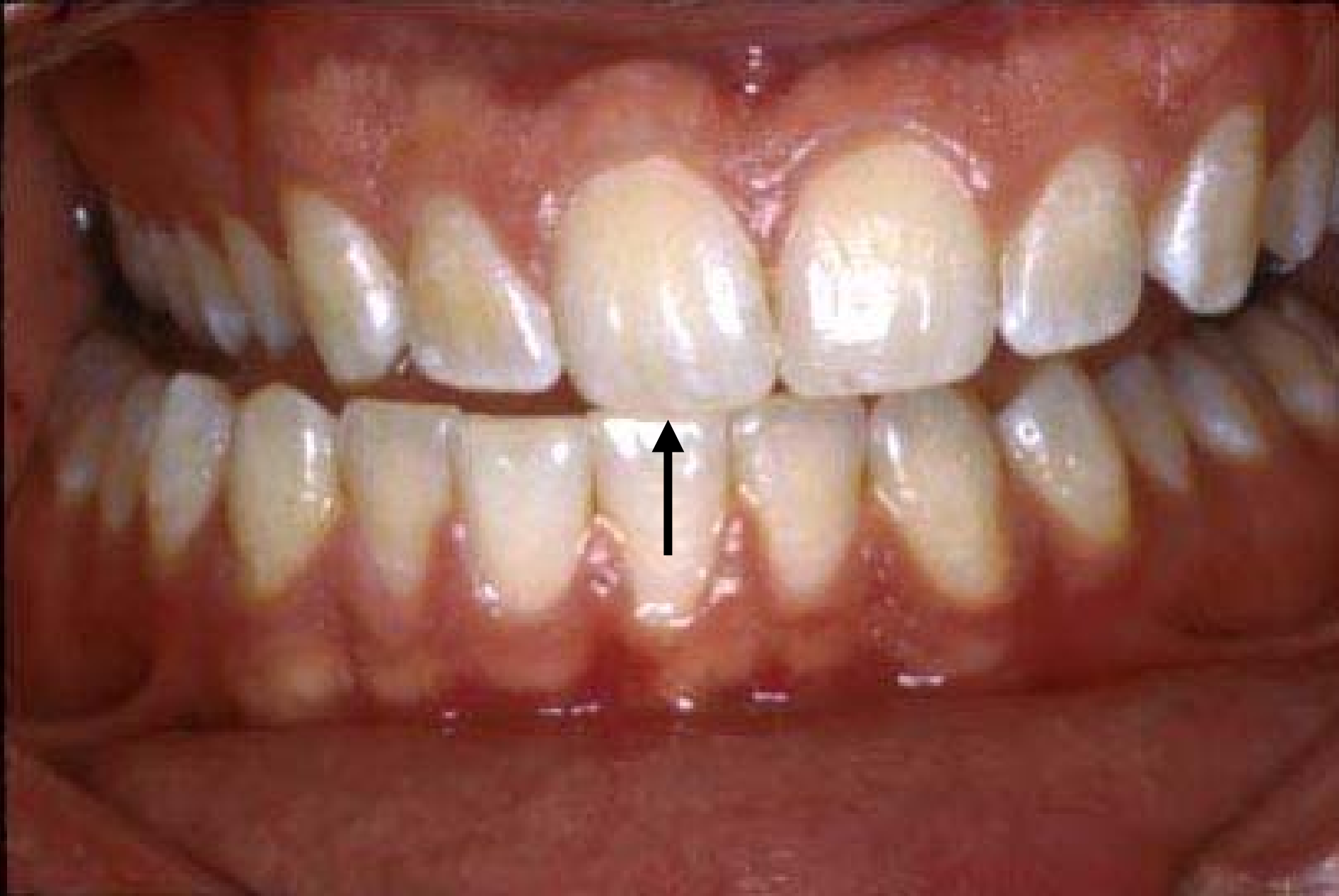

A66

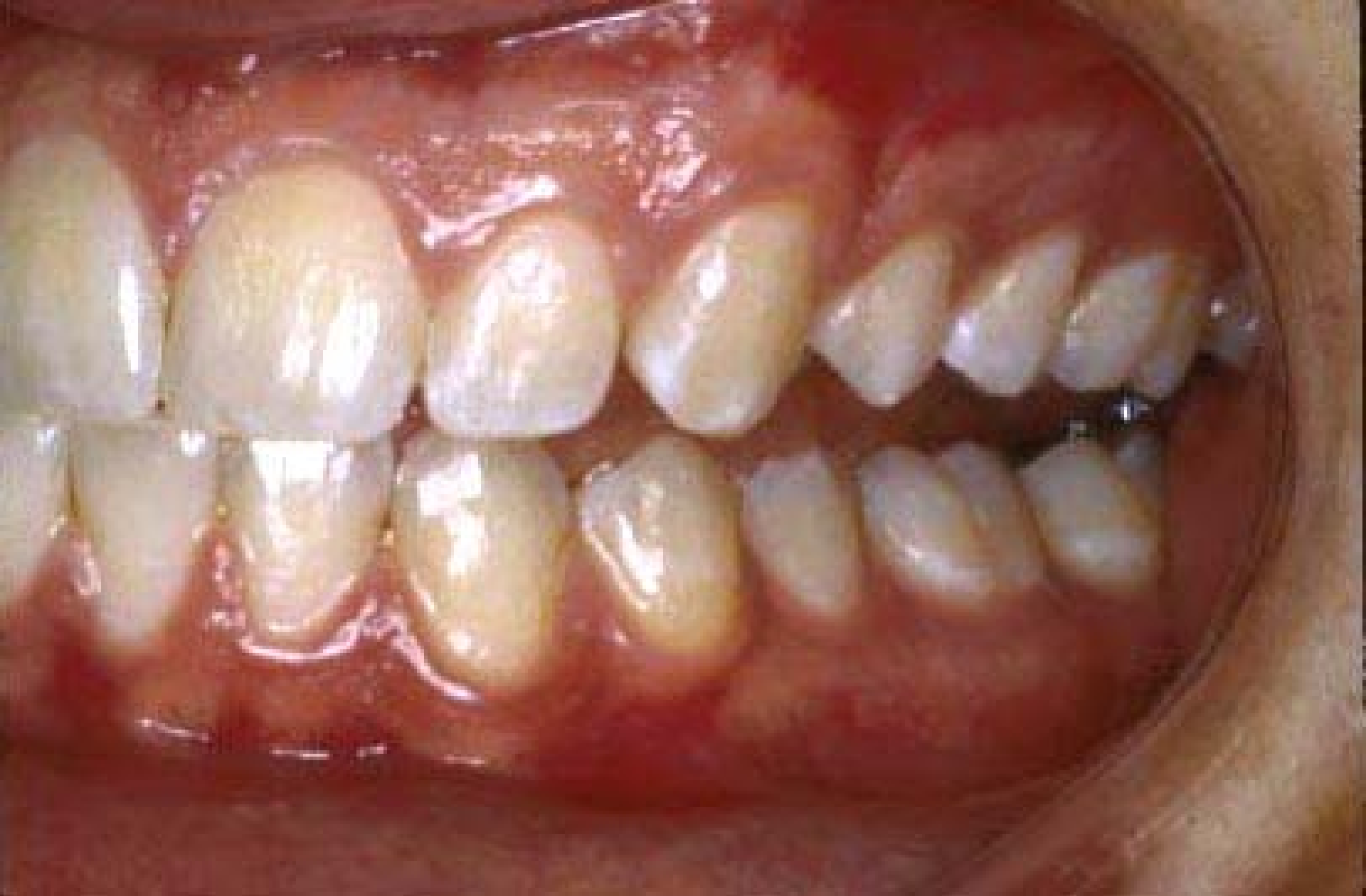Nicely aligned teeth. (Class I occlusion)



A67 Cuspid rise - right side. No posterior teeth in contact.

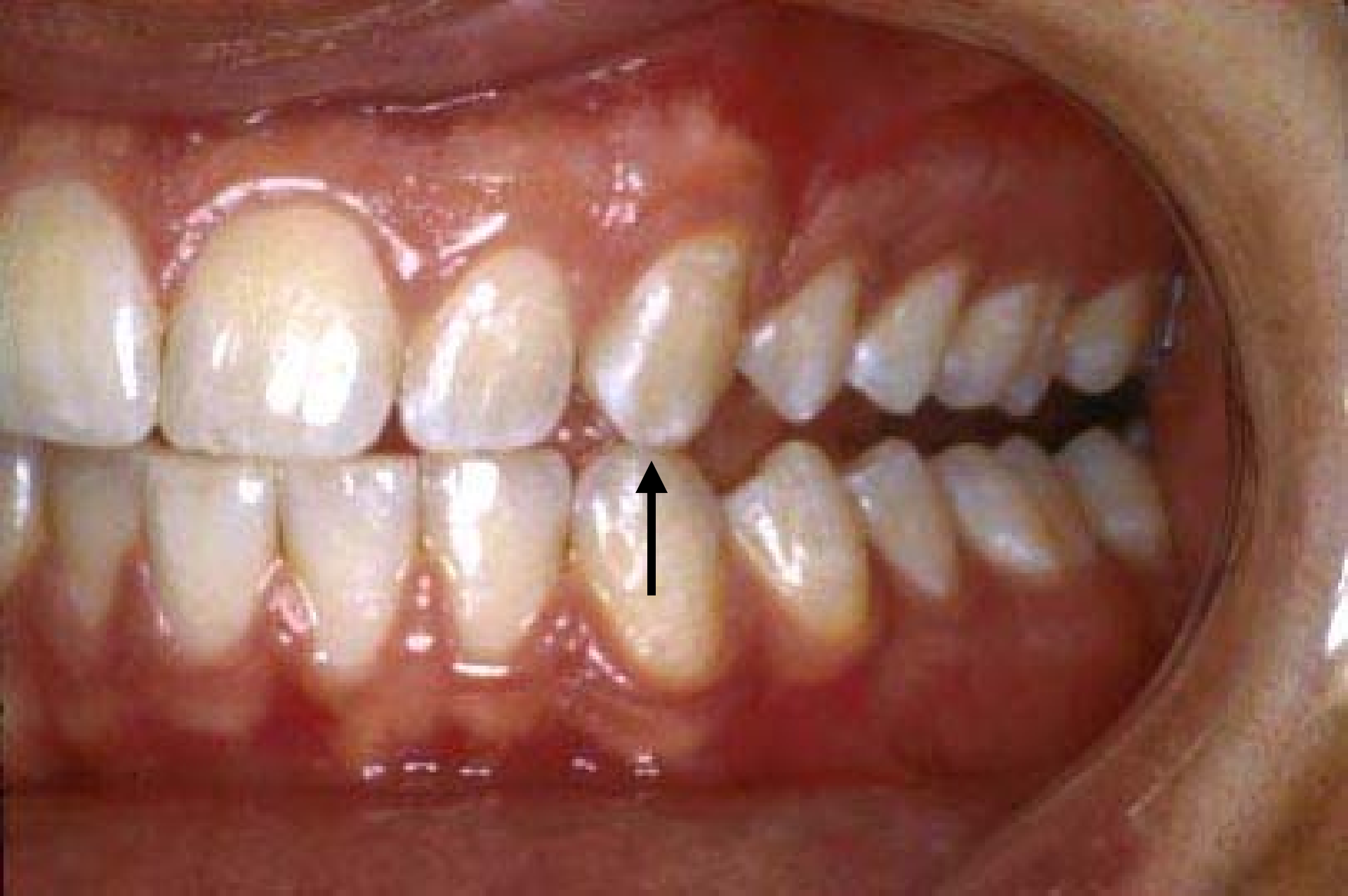

During crossover, guidance is from anterior teeth.

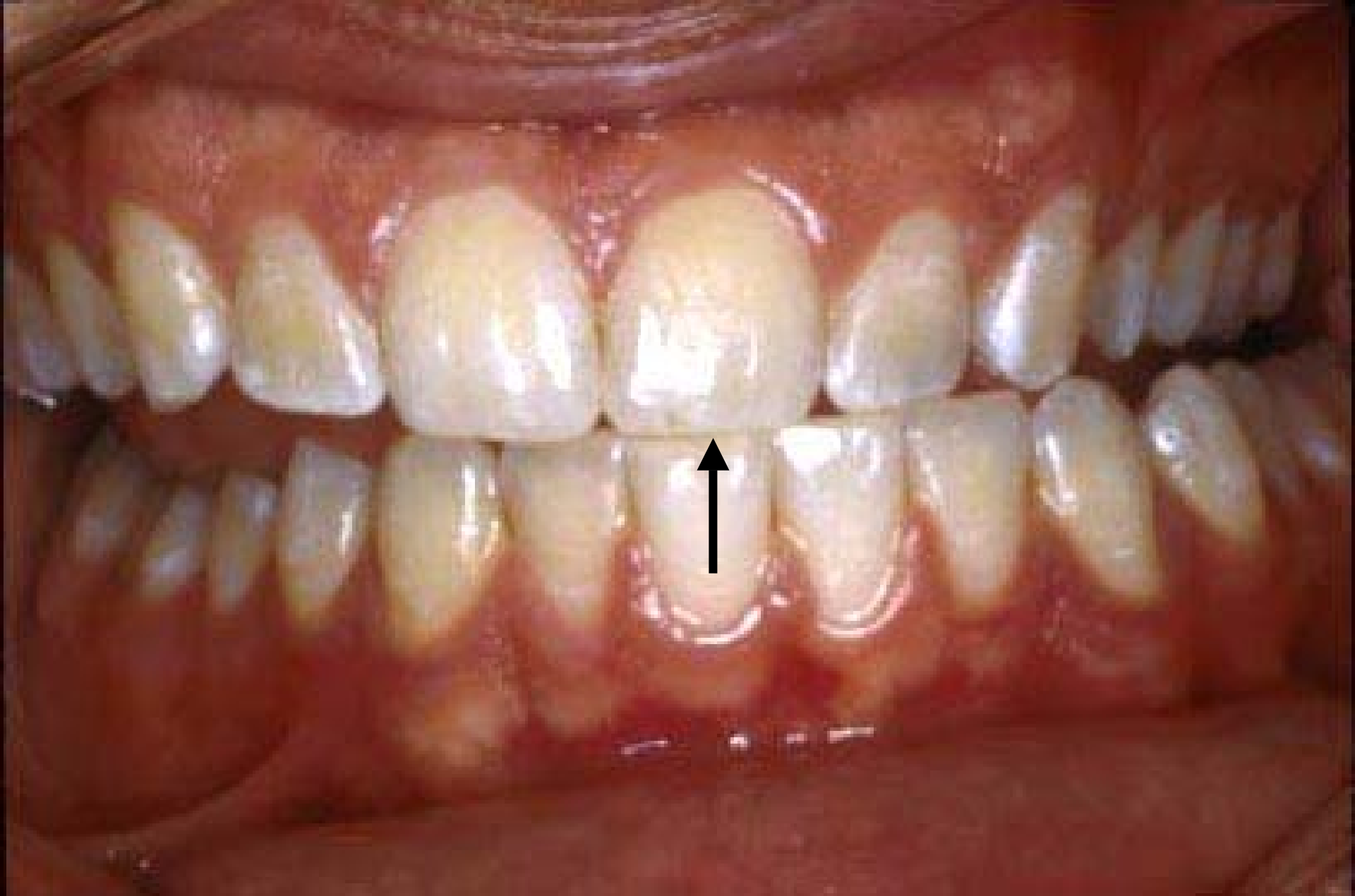

During crossover, none of the posterior teeth on other side are contacting either.

A69



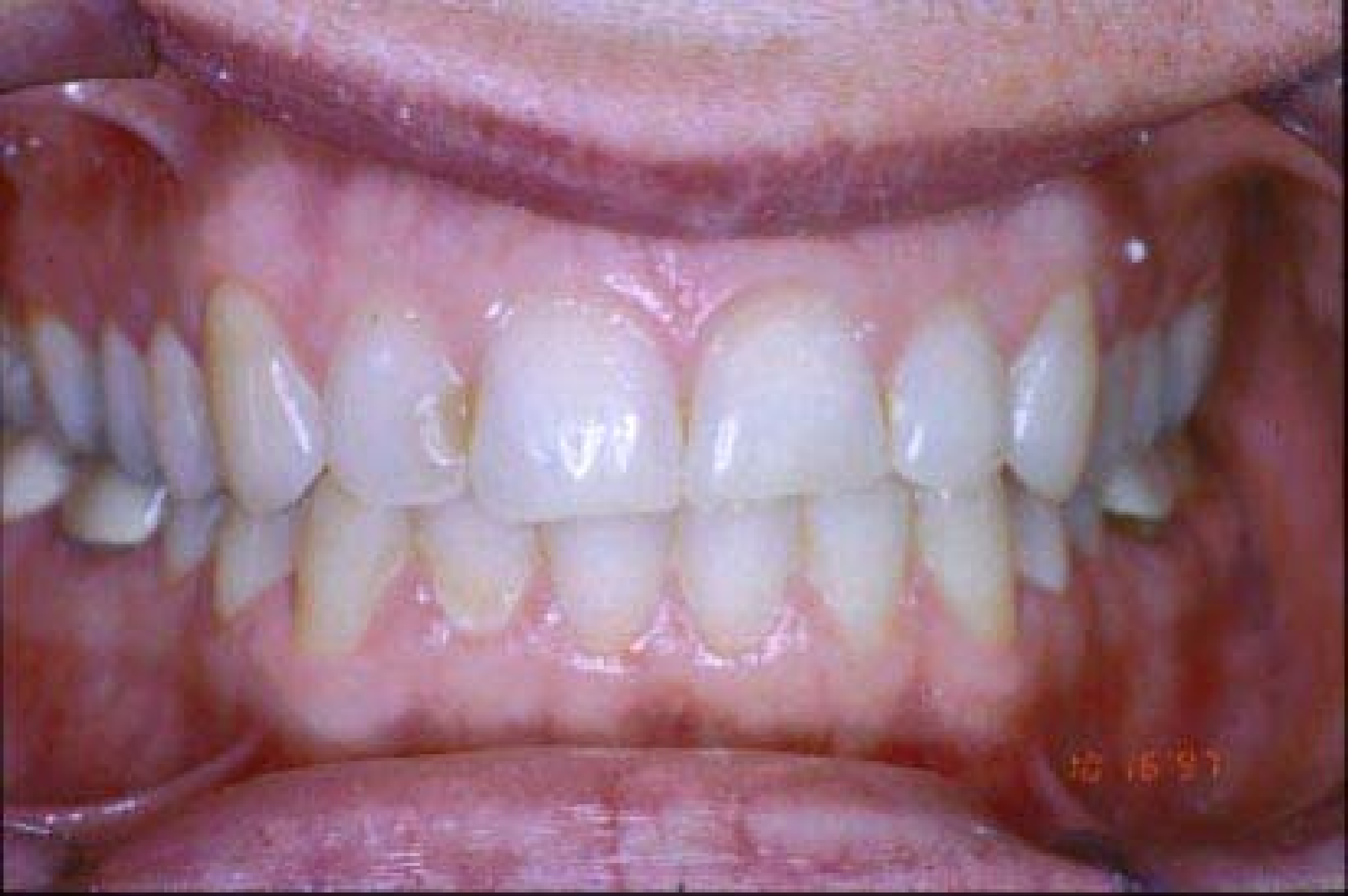A70 Cuspid rise going in other direction. No posterior contacts.



A71 Crossover going in other direction. No posterior contacts.

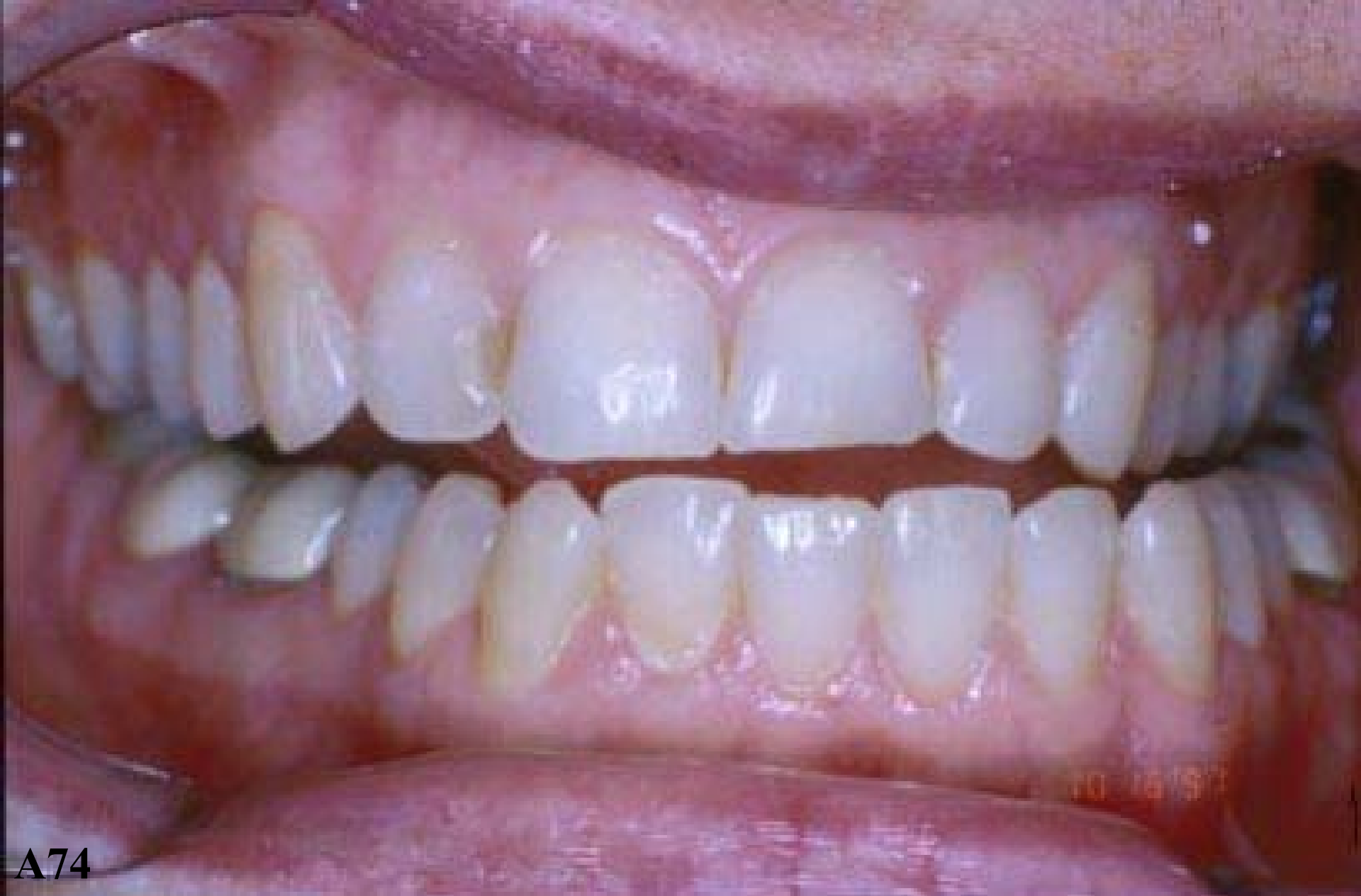Malocclusion

Traumatic Occlusion



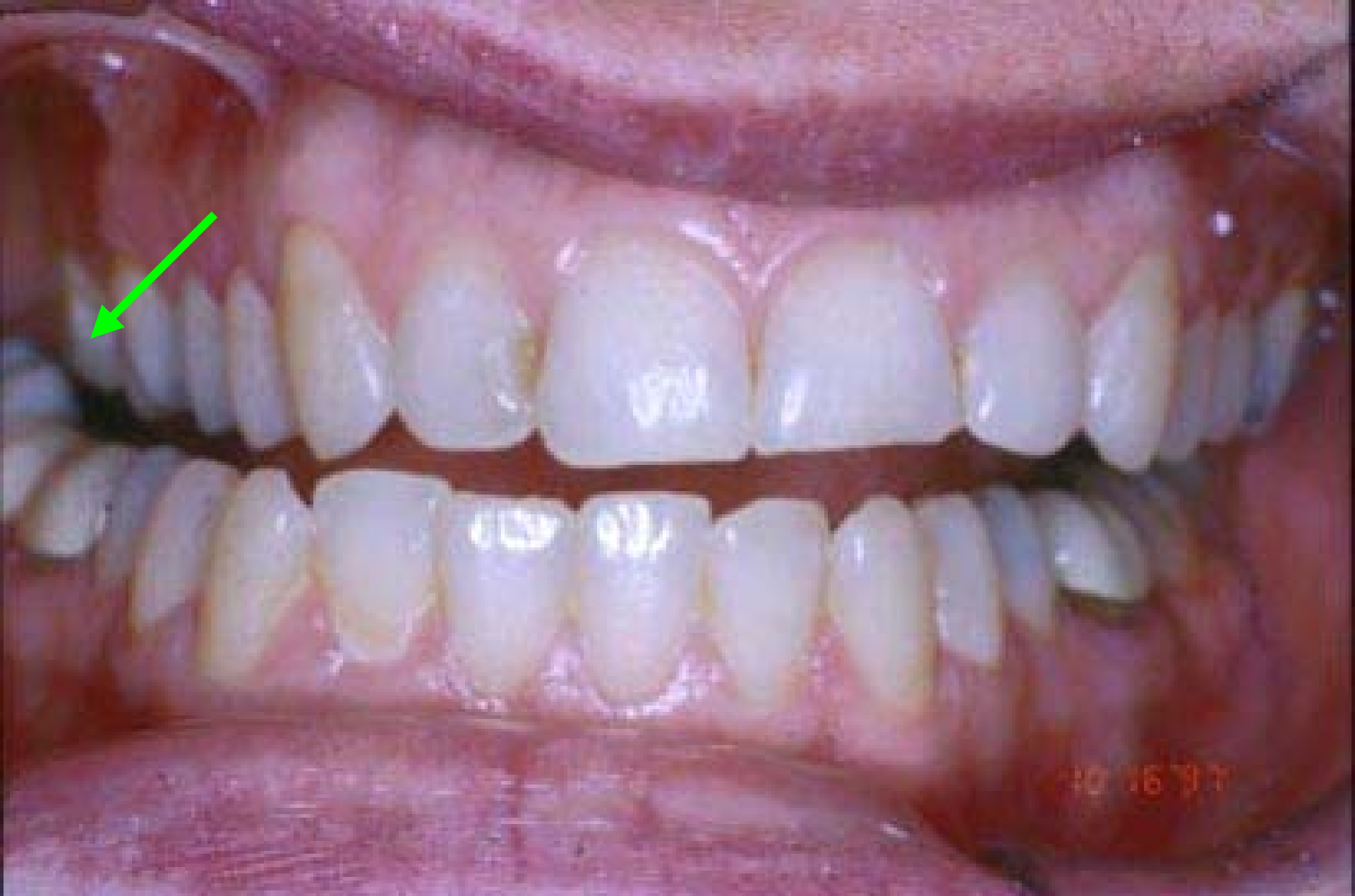Anterior view during closure.

A73





A74

Guidance coming from posterior tooth during excursion.



A75

Problem tooth causing interference and discomfort.



Maxillary lingual cusp tip below the Curve of Wilson. Interferes during excursions.

“X” Factors that effect breakdown.

- **Emotional stress**
- **Physical stress**
- **Ability to cope**
- **Heredity**
- **Age**
- **Diet**
- **Growth and Development**
- **Illness and disease**
- **Physical environment**
- **Habits**
- **Factors still unknown.**

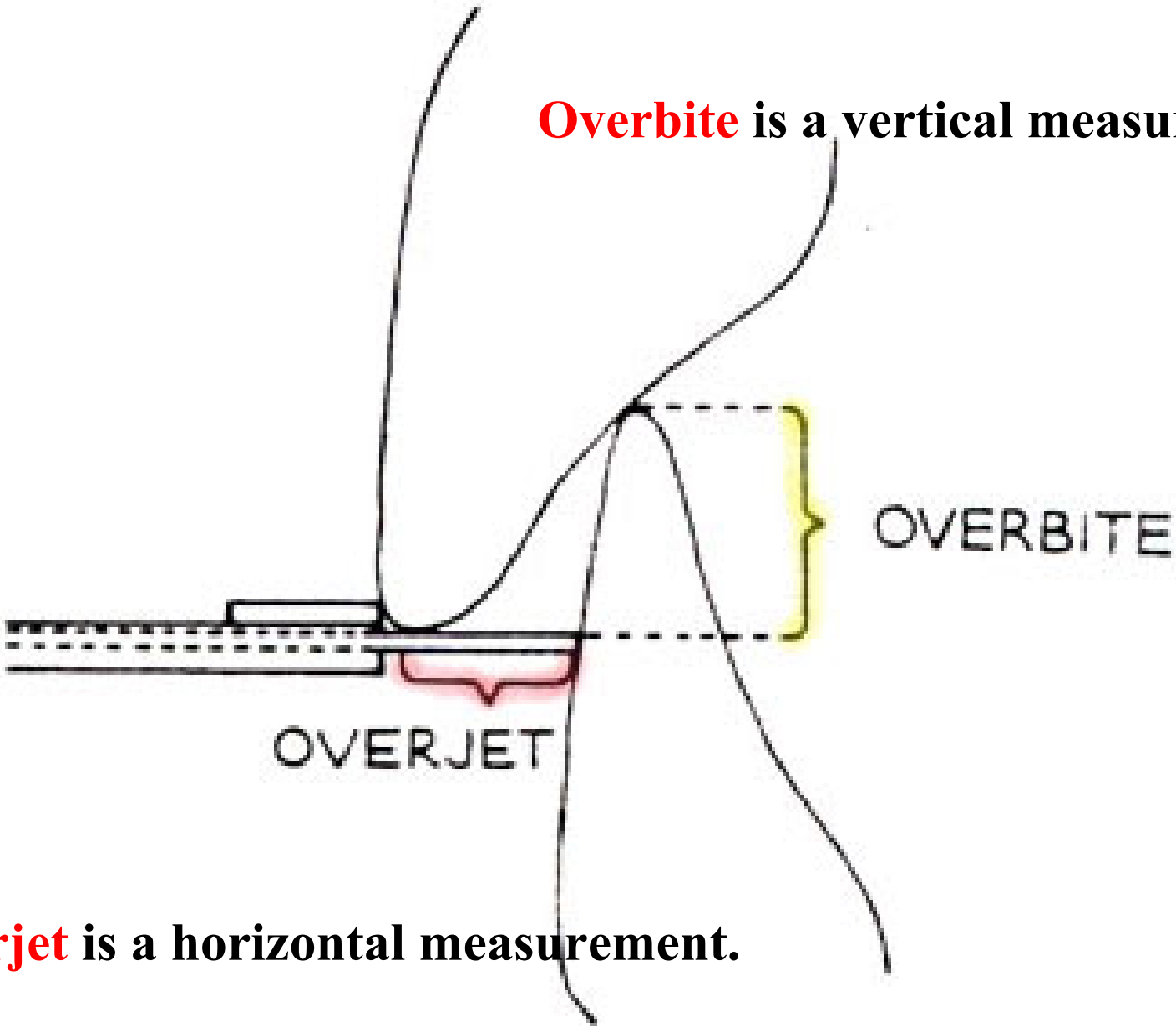
Possible consequences if principals not followed:

- Bone loss / loose teeth / lost teeth.
- Abfractions / recession / clefts.
- Tori.
- Flattened occlusion.
- Cracked teeth.
- TMJ breakdown.

Occlusion Terms

- Overjet / Overbite.
- Class I occlusion: Adult and Pedo.
- Class II malocclusion, Div 1 & 2.
- Class III malocclusion.
- Cross-bite.

Overbite is a vertical measurement.



Overjet is a horizontal measurement.

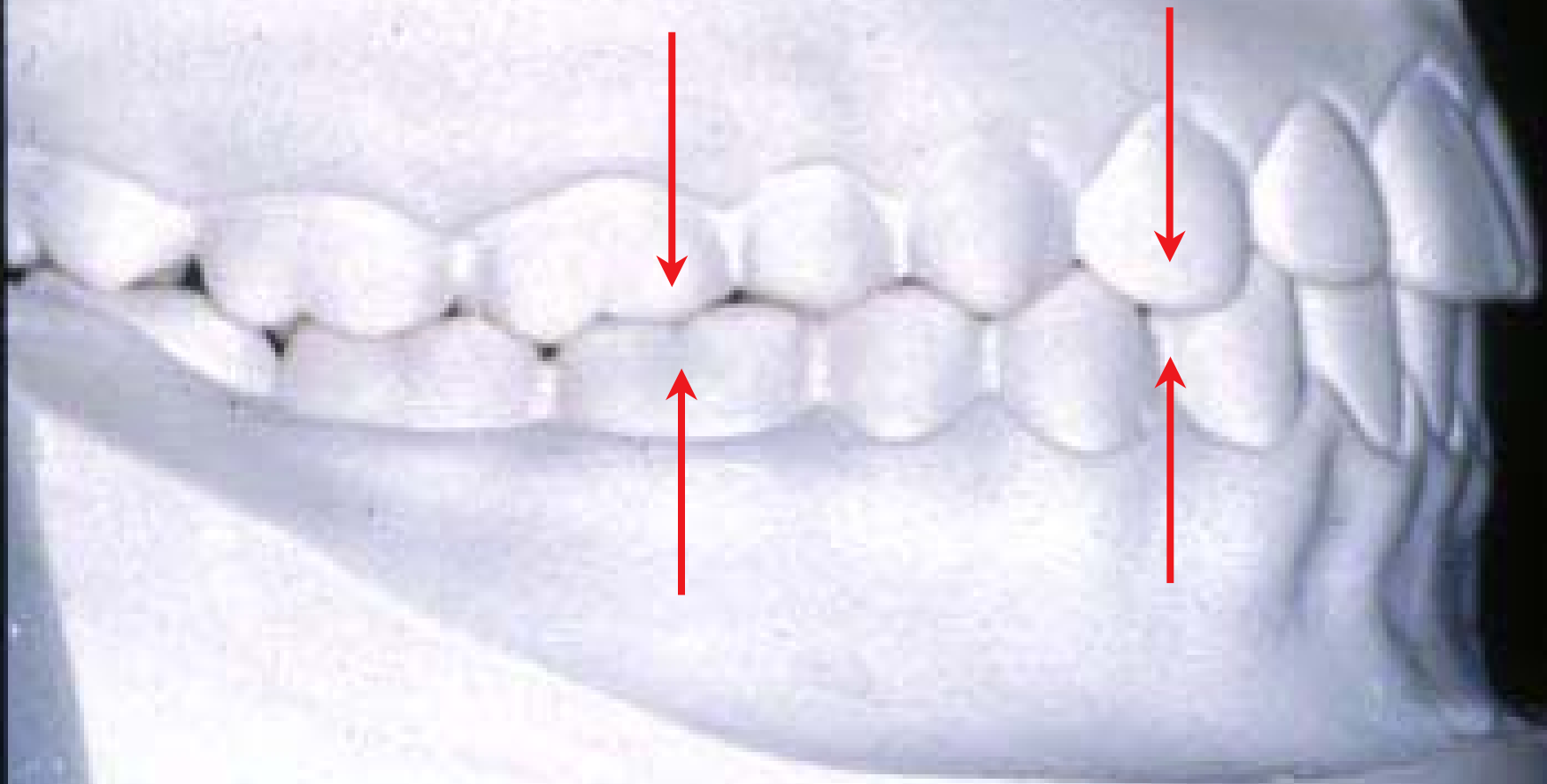
Class I occlusion.

Best occlusion.

Breastfed individual have the best chance of having this ideal occlusion.

Arrows are where they should be.

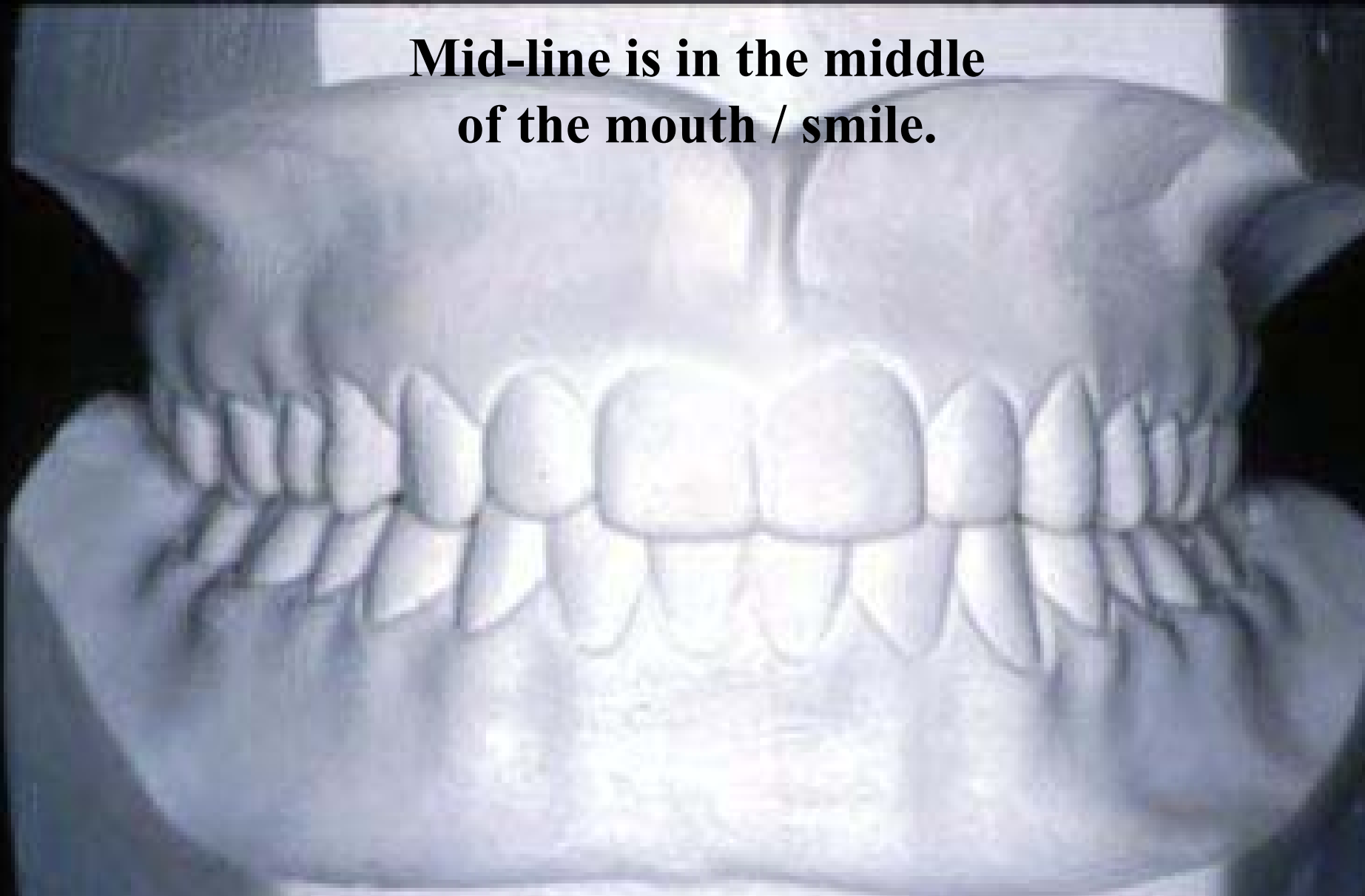Has ideal overjet and overbite.



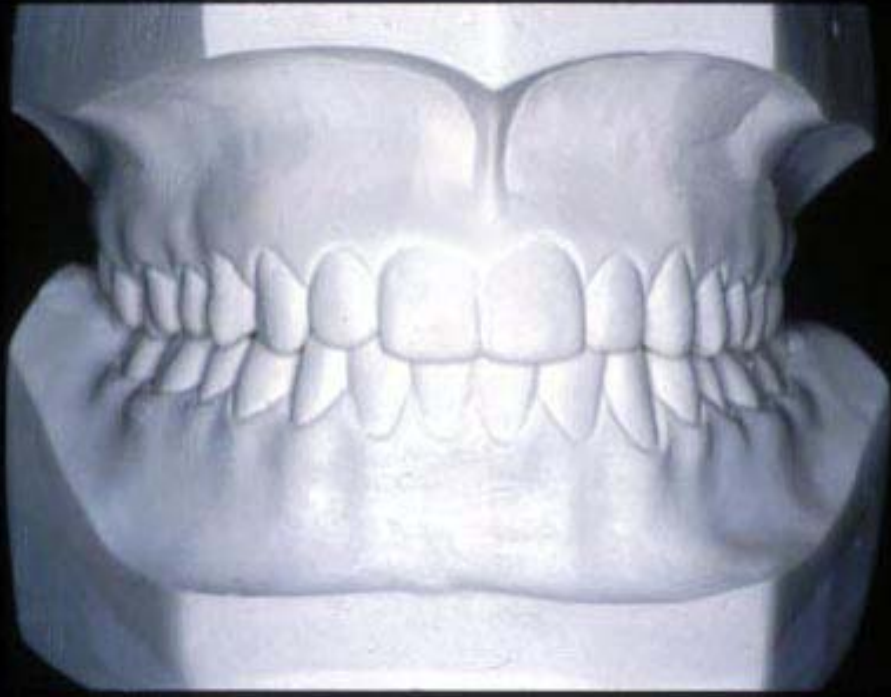A82

Adult Class I (Lateral view)

**Mid-line is in the middle
of the mouth / smile.**

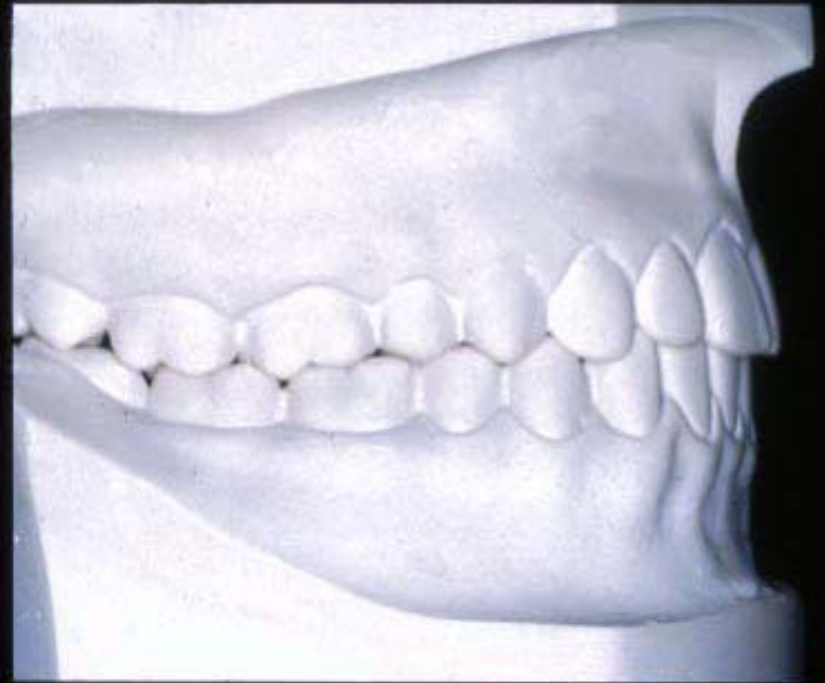


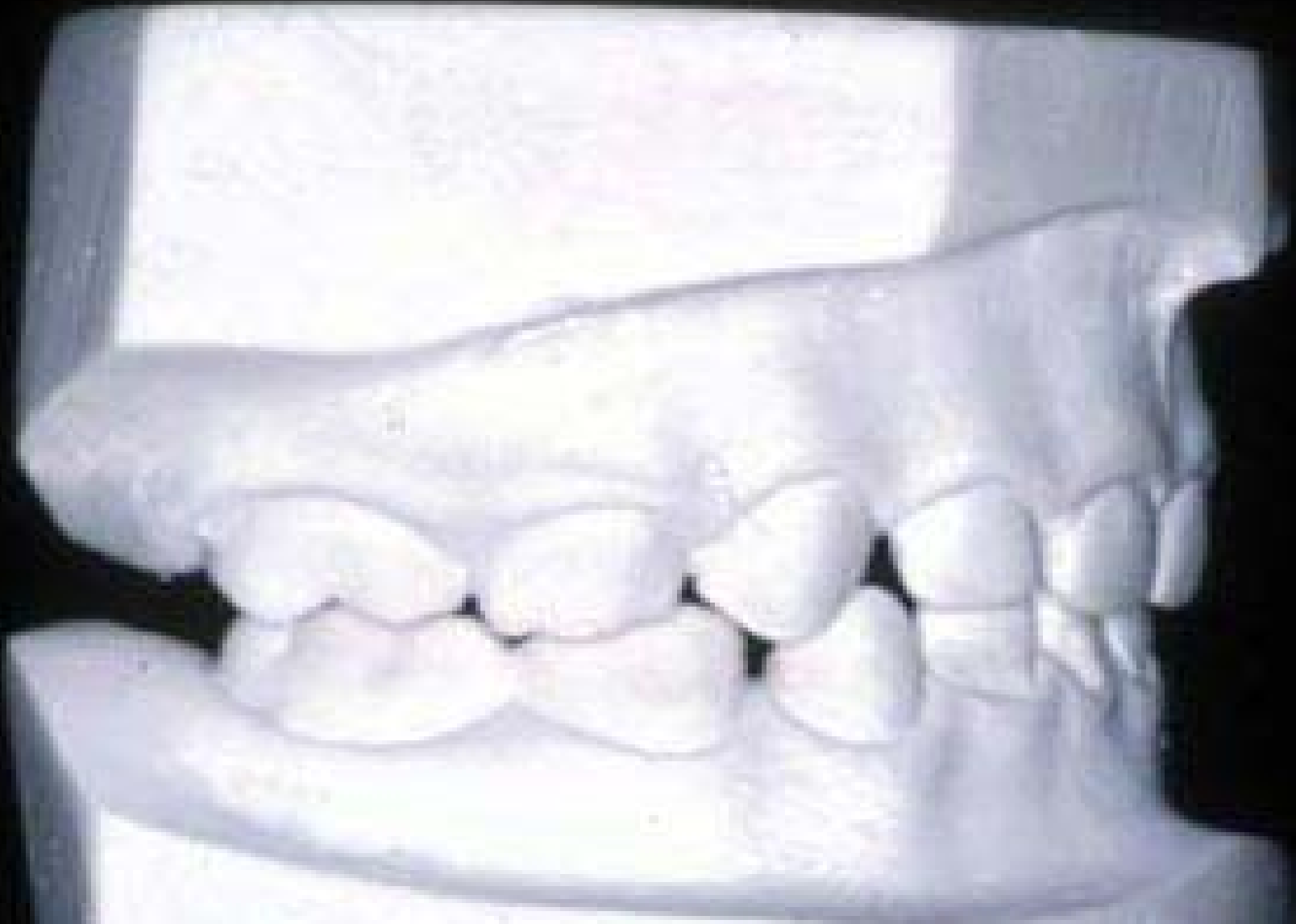Adult Class I (Anterior view)



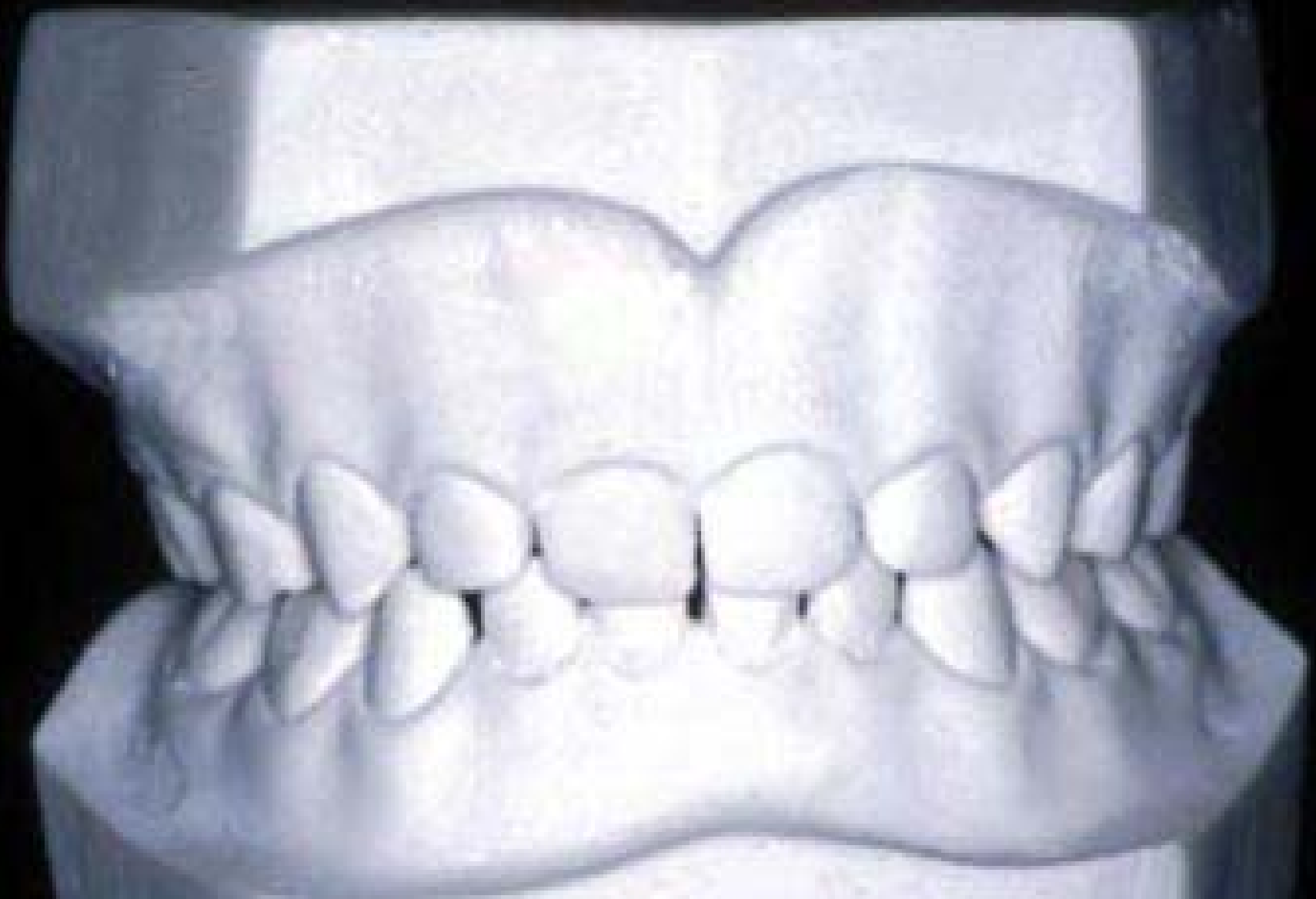Adult Class I

Best occlusion.



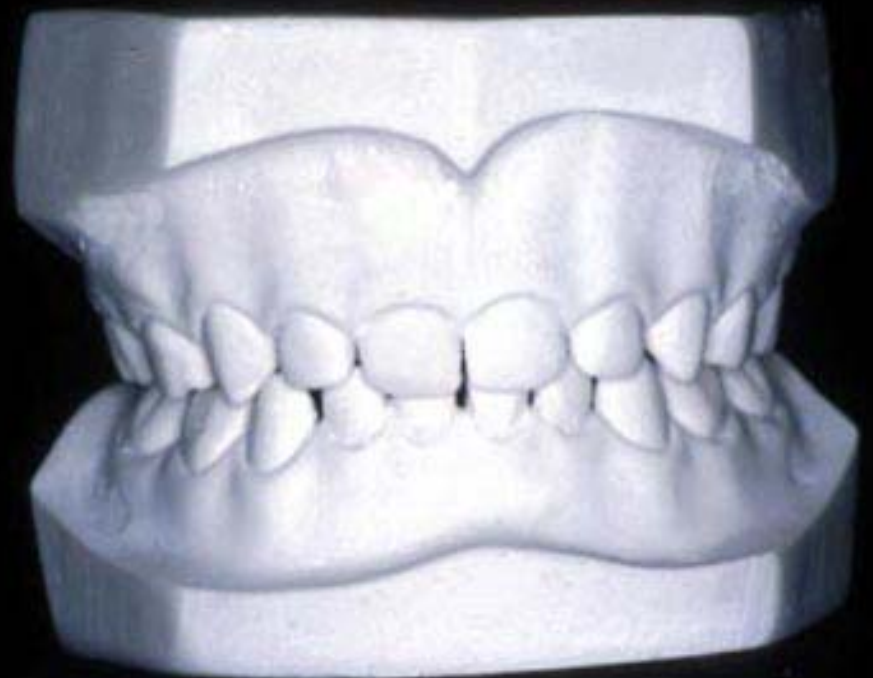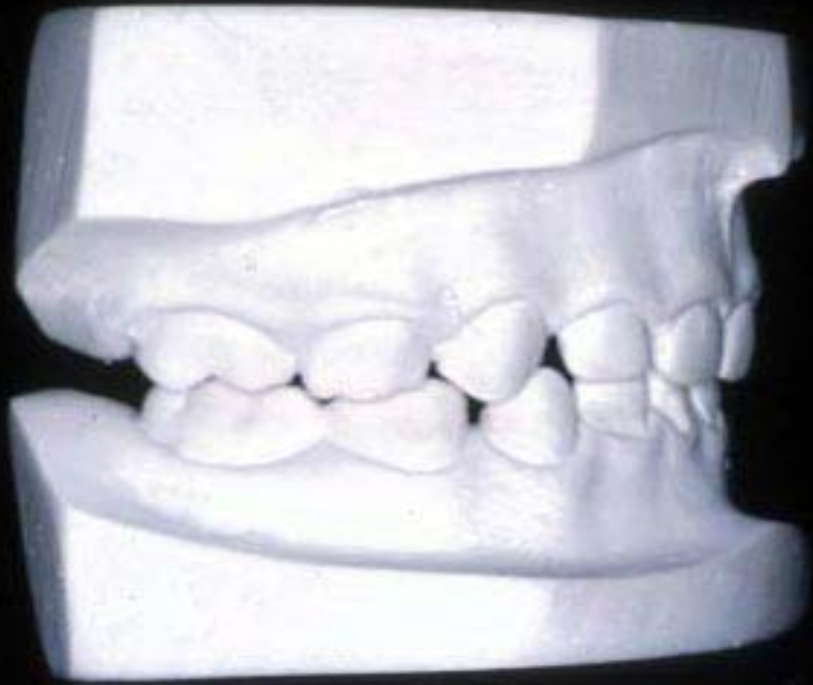


Child's Class I (Lateral view)



Child's Class I (Anterior view)

Child's Class I



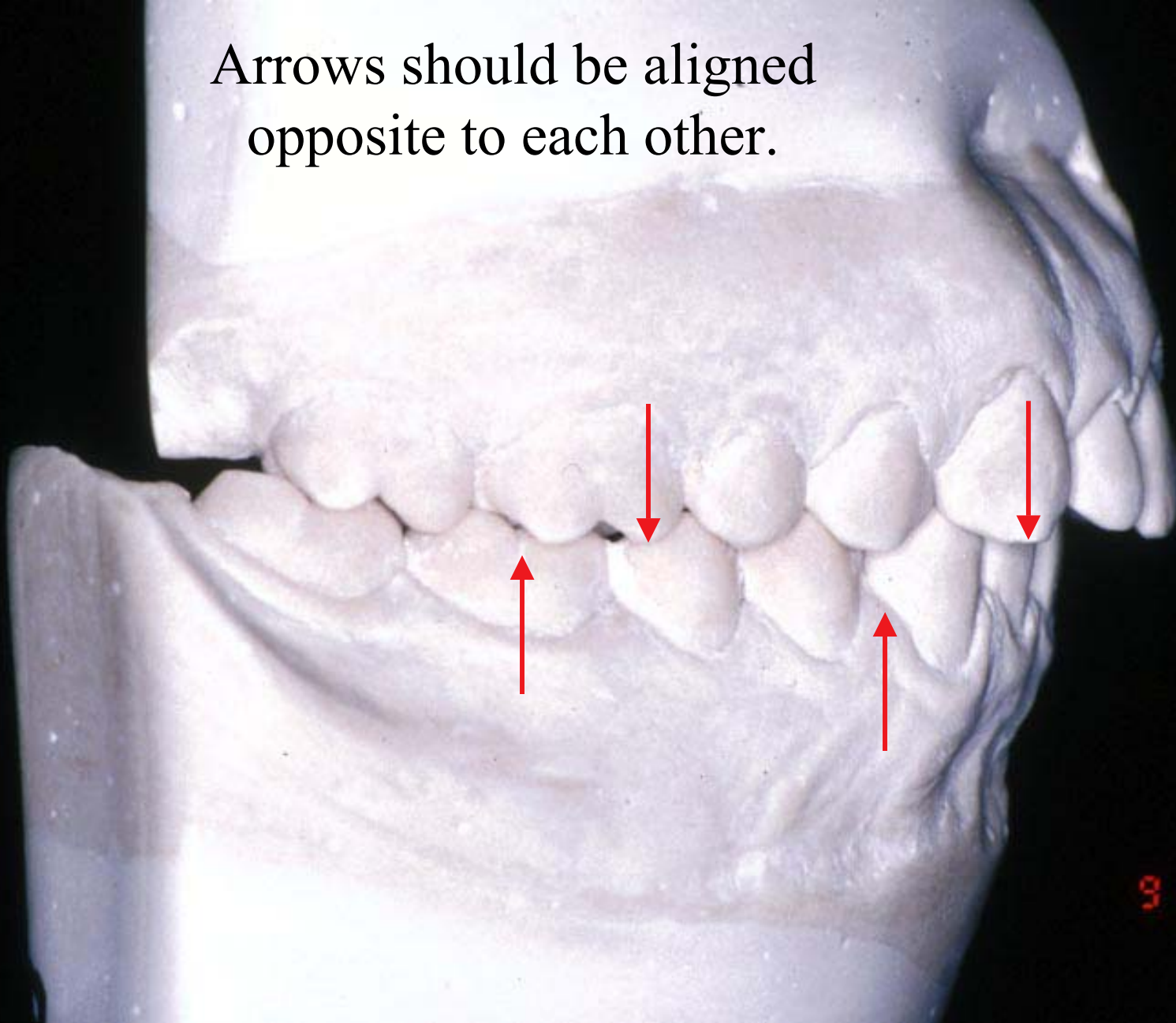
Class II malocclusion.

Retrognathic - 'pushed back jaw'- malocclusion.

Potentially deadly if it contributes to, or is a causative factor in, the development obstructive sleep apnea (OSA). It is the most common malocclusion in individuals with OSA.

Major contributors to this malocclusion are: bottle feeding, pacifier use, excessive noxious habits and early obstruction / airway resistance of the airway.

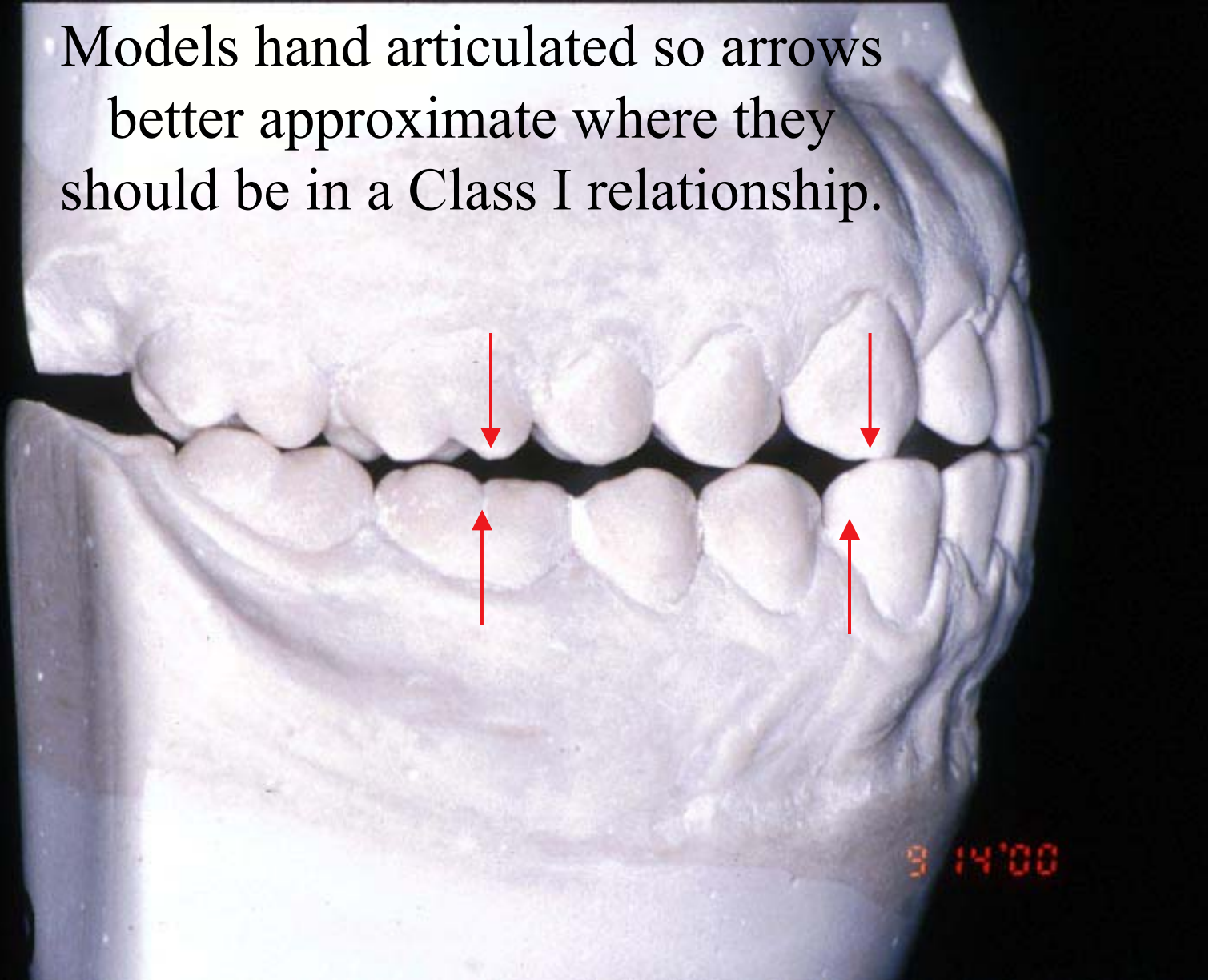
Arrows should be aligned
opposite to each other.



A89

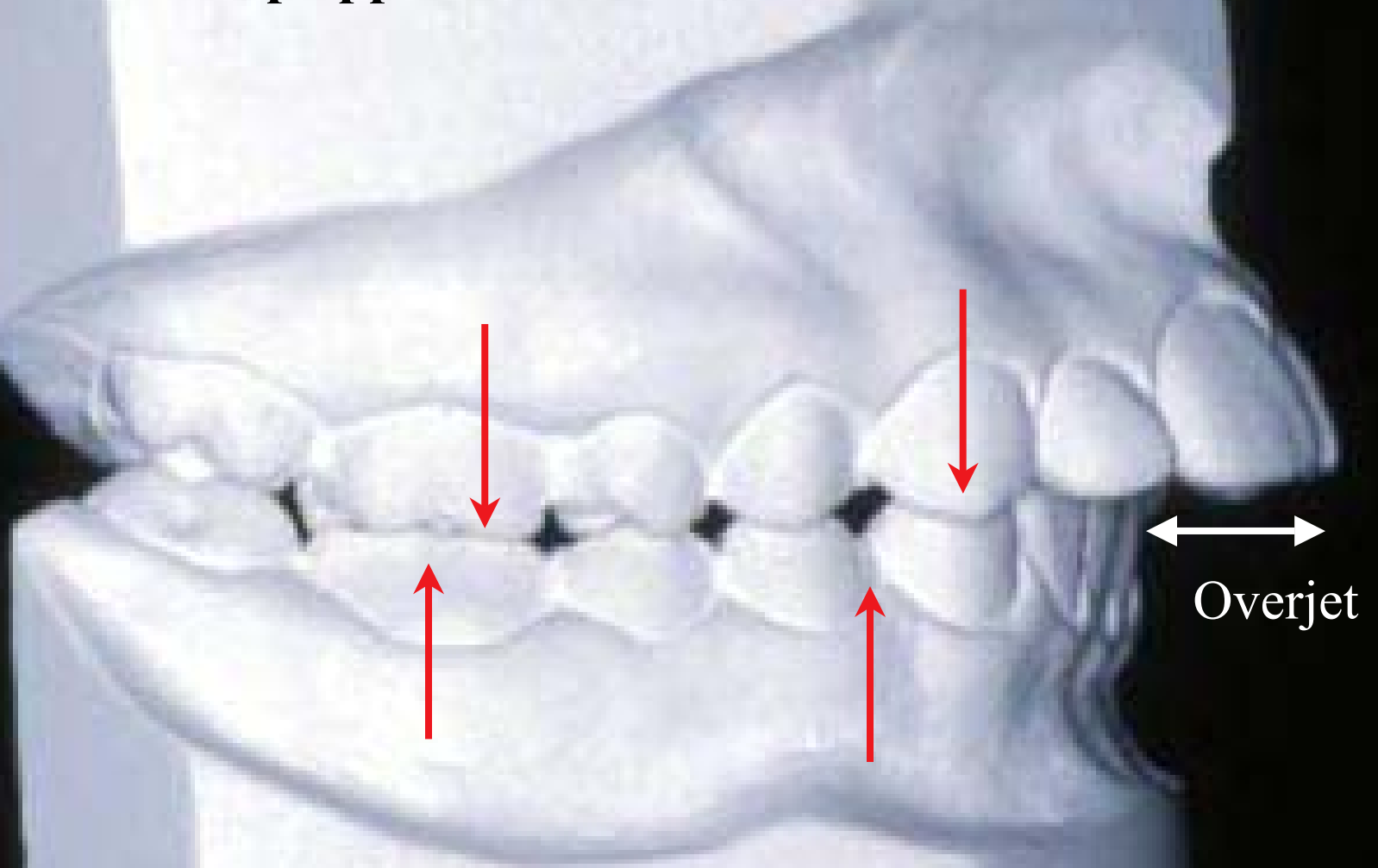
Class II - retrognathic malocclusion

Models hand articulated so arrows better approximate where they should be in a Class I relationship.



Previous models positioned to a Class I occlusion

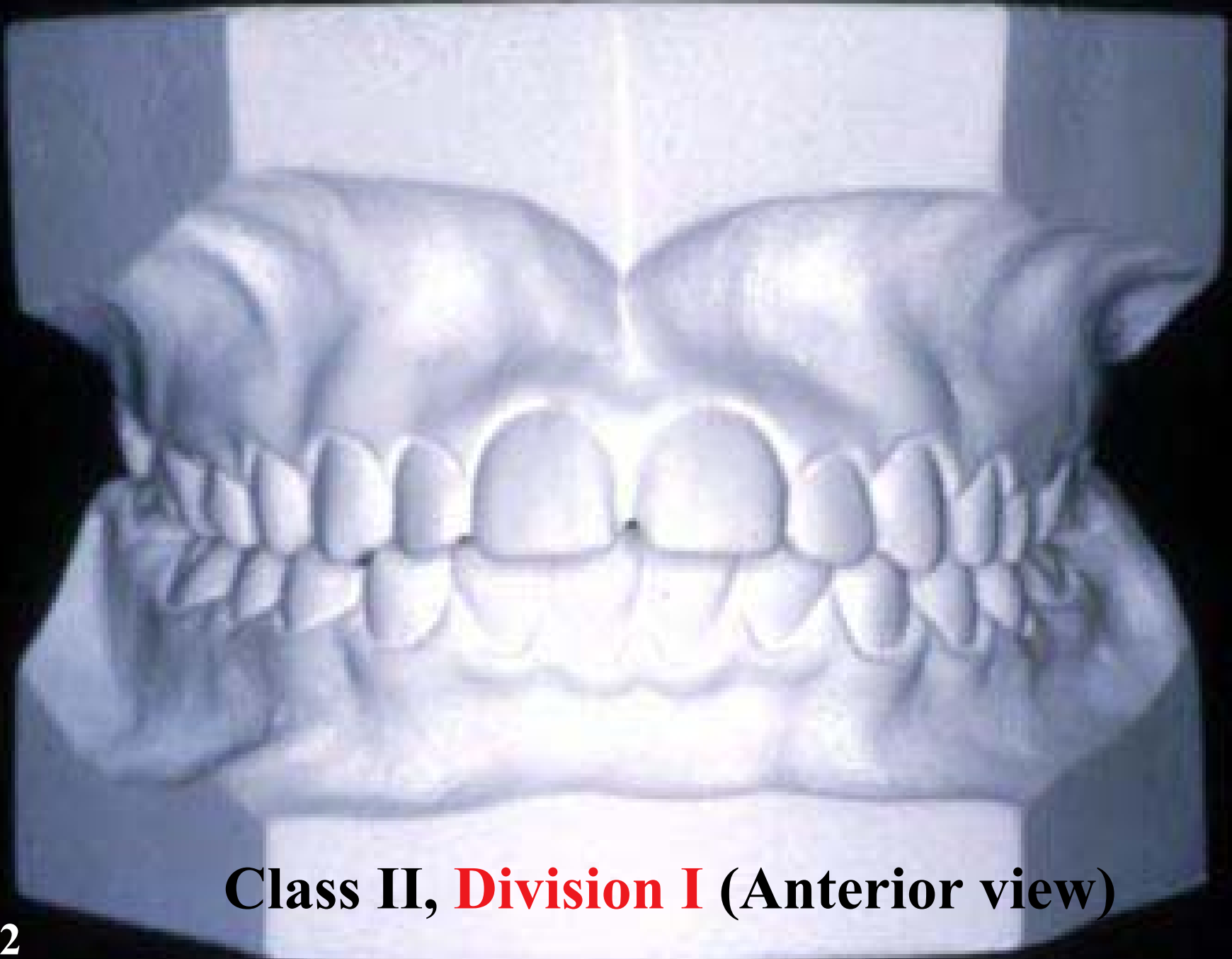
**Red arrows should line
up opposite each other.**



Overjet

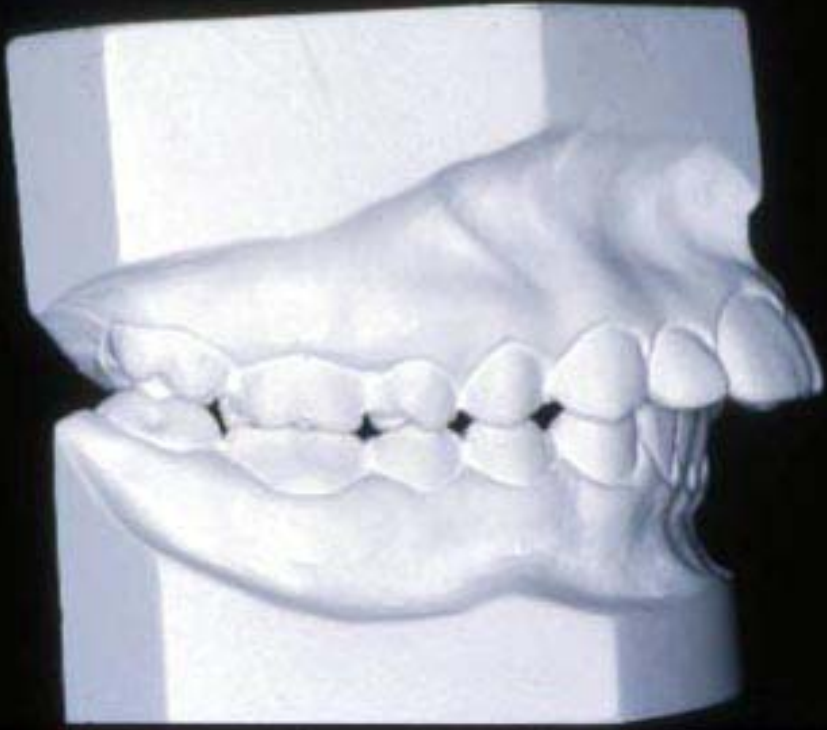A91

Class II, Division I (Lateral view)



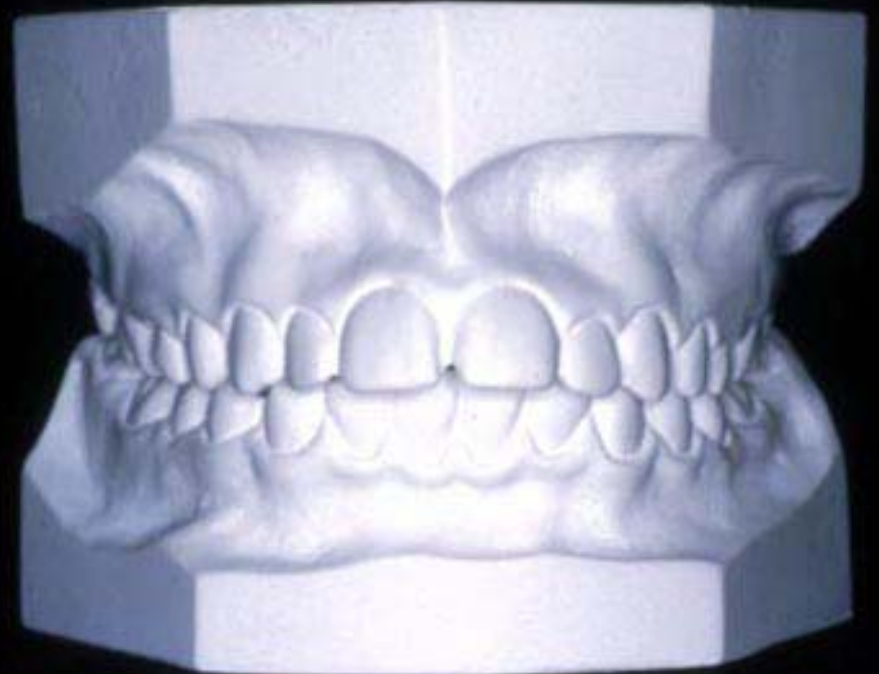Class II, Division I (Anterior view)

Class II, Division 1

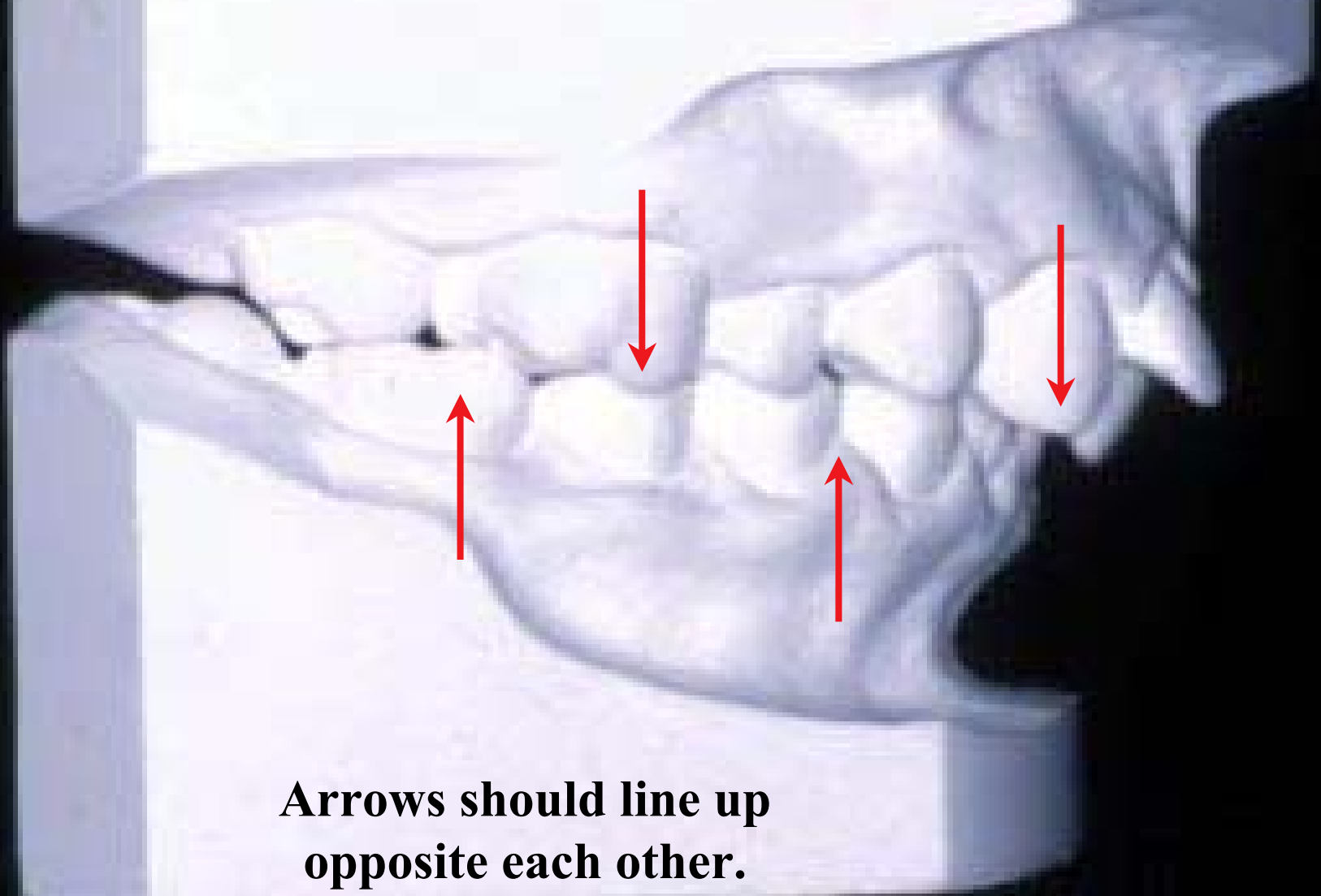


Upper anterior teeth flare out.

A93

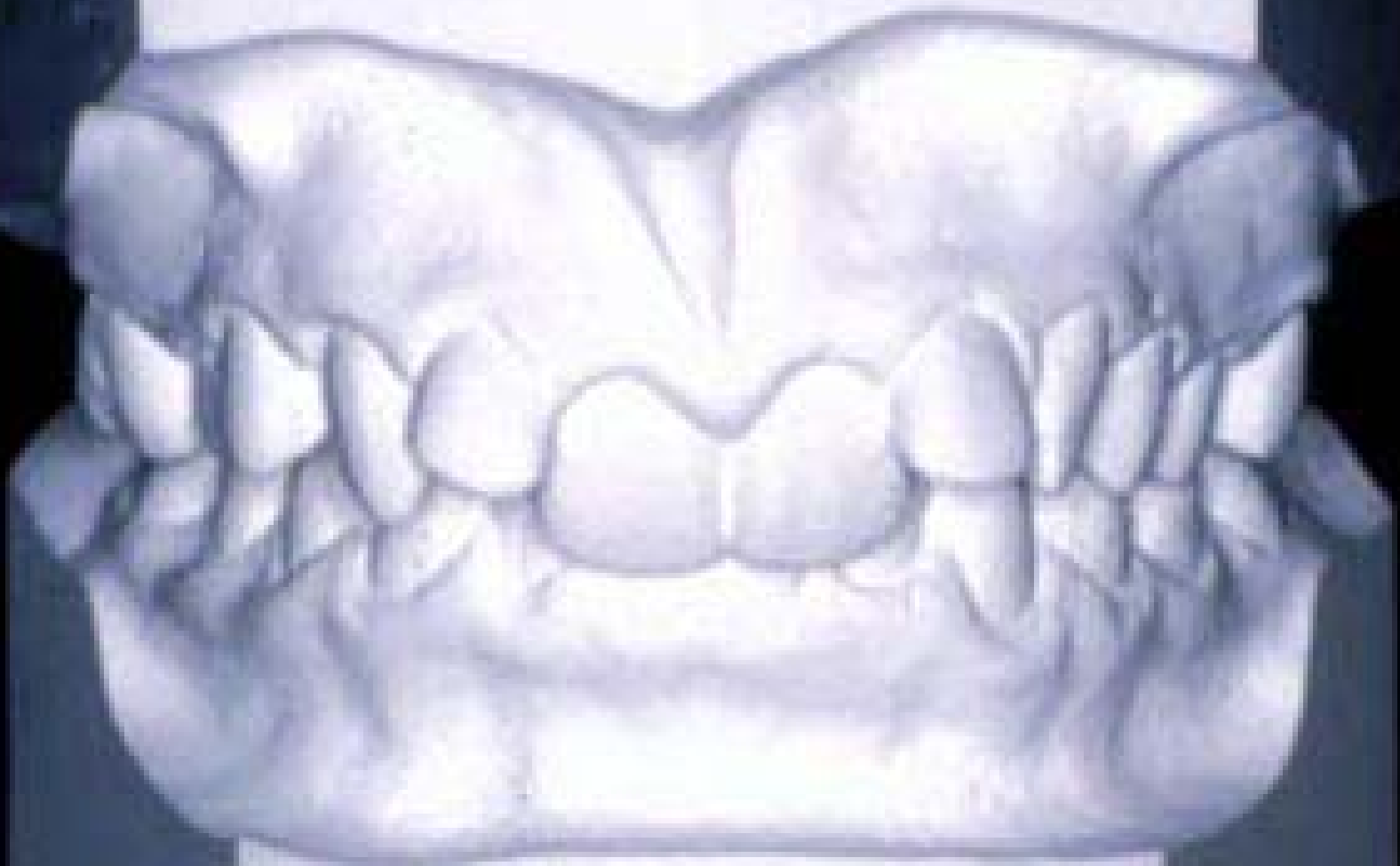

Class II, Division 2 (Lateral view)



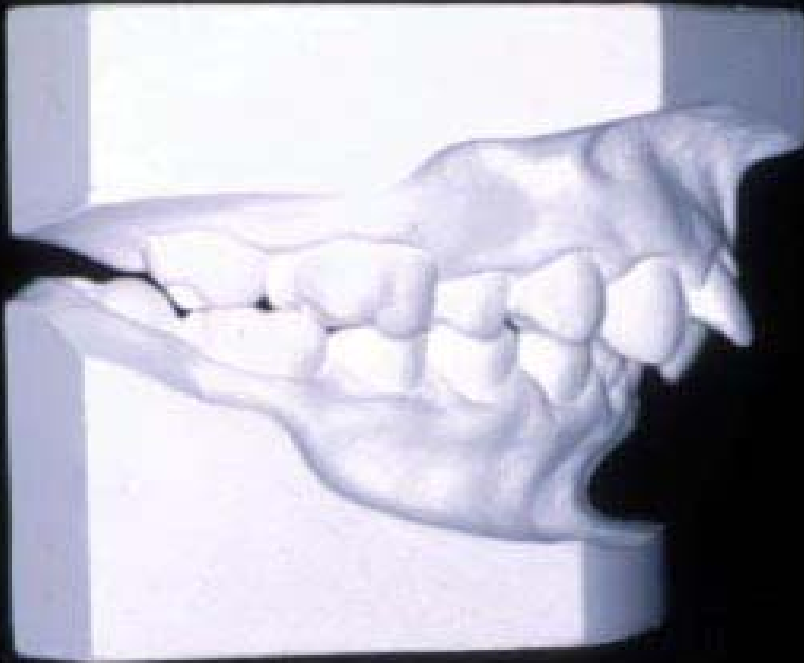
**Arrows should line up
opposite each other.**

Class II, Division 2 (Anterior view)

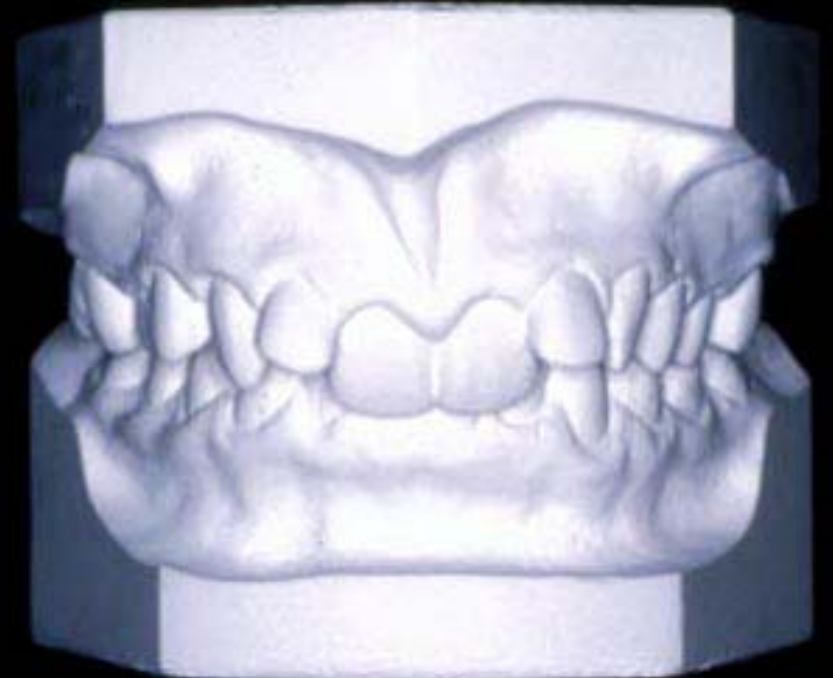

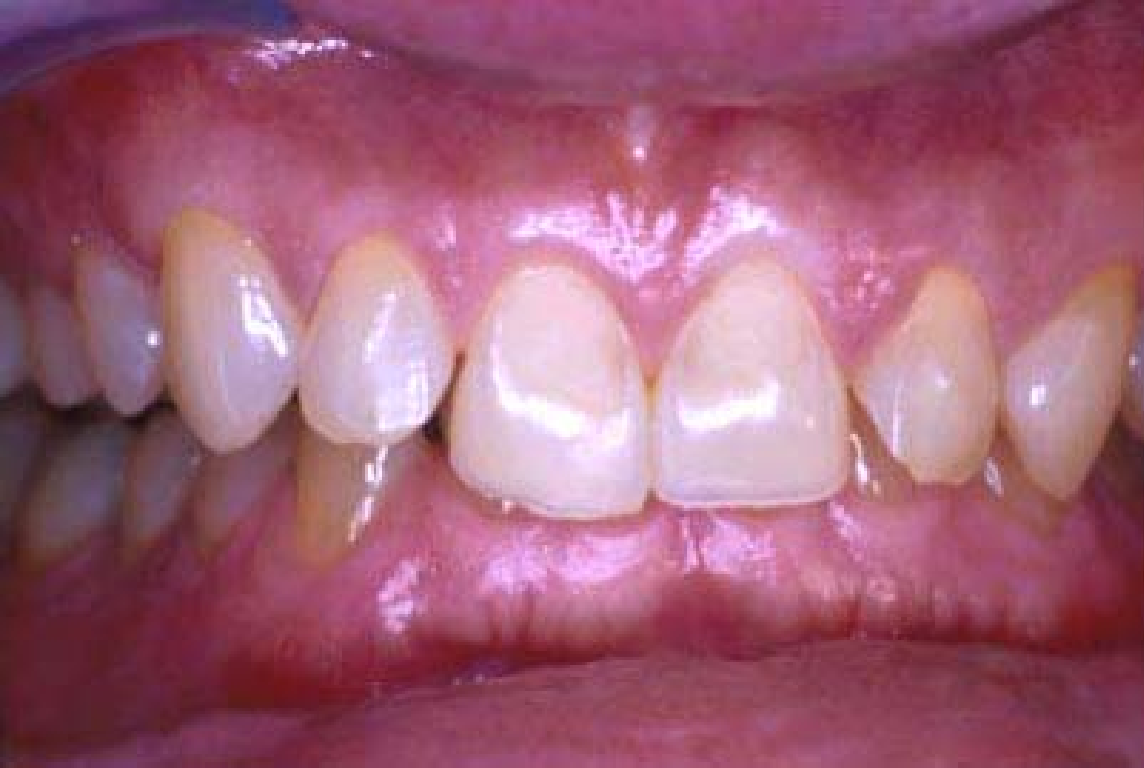Note slant of upper 4 anterior teeth.

Class II, Division 2

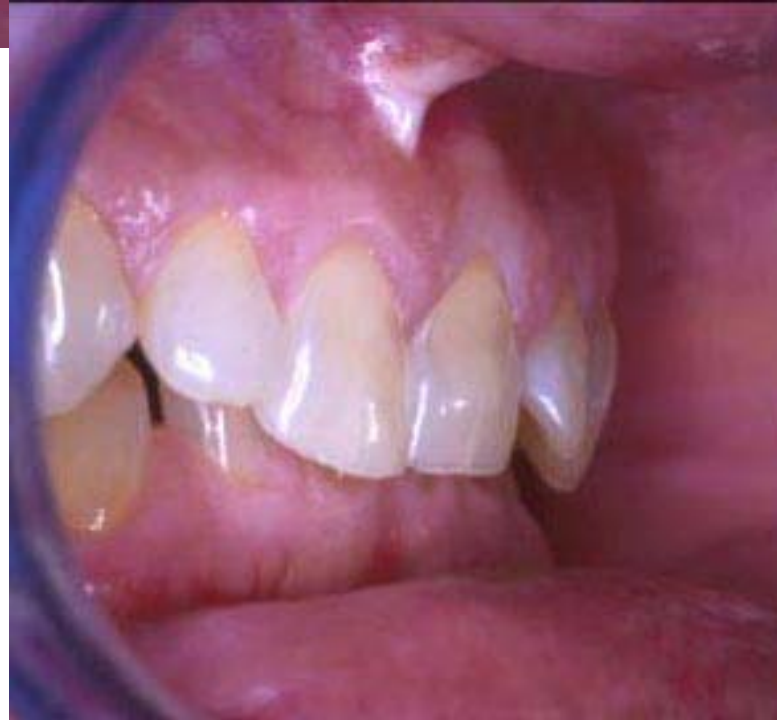

Central 2 teeth slant inward,
adjacent lateral teeth slant out.





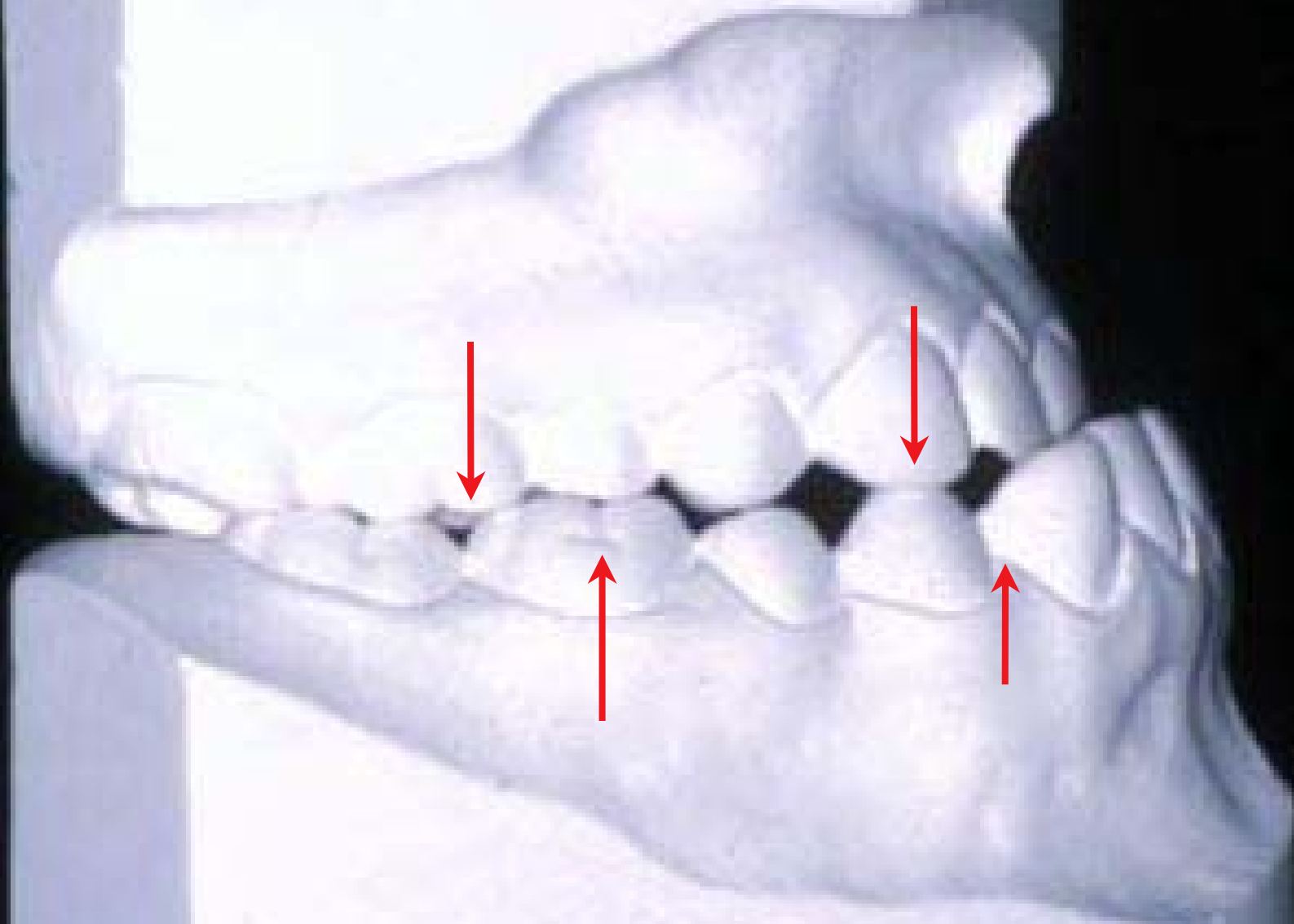
Note significant overbite on this Class II malocclusion.



Class III malocclusion.

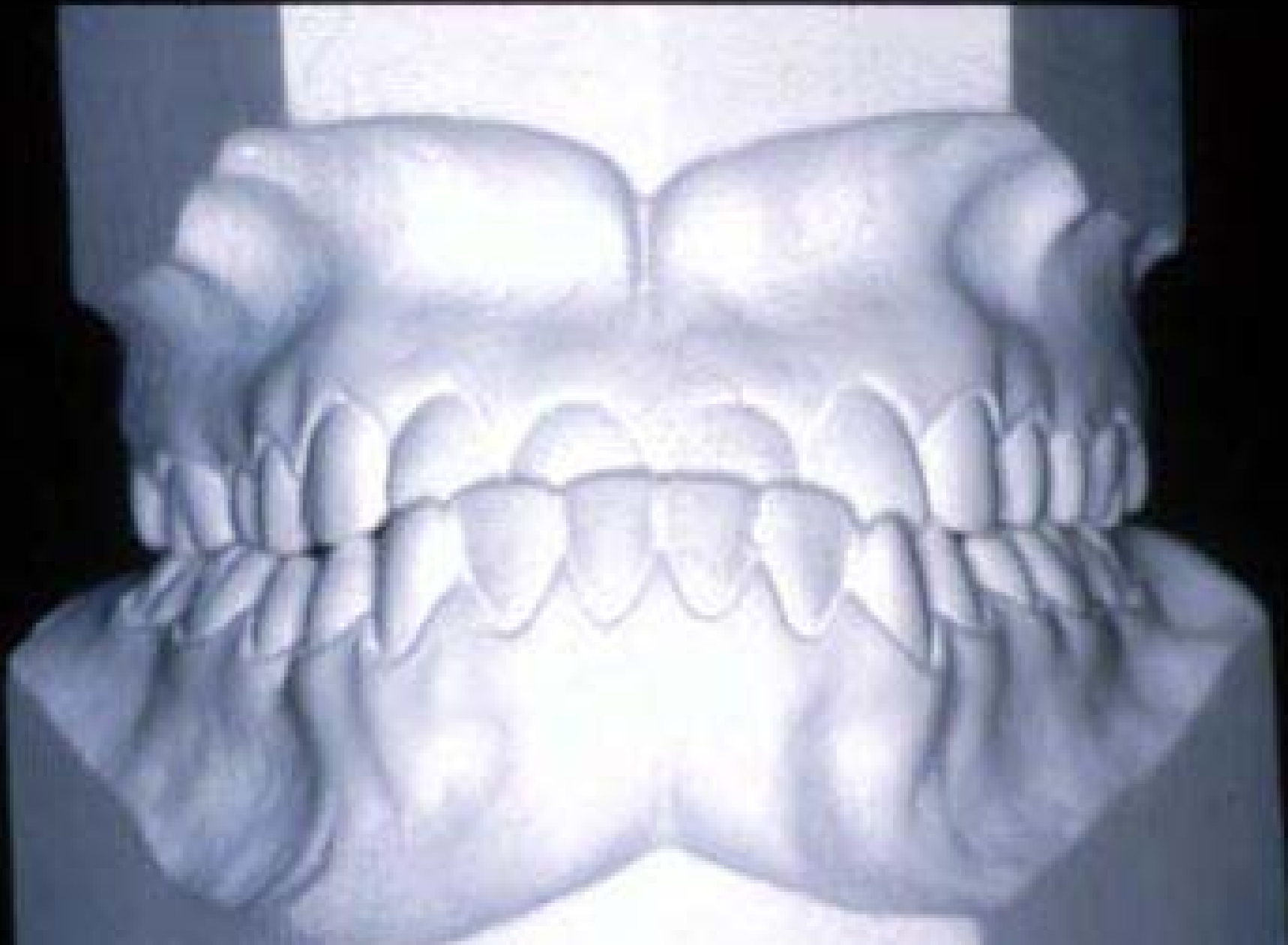
The 'bulldog look'.

Arrows should line up.



A99

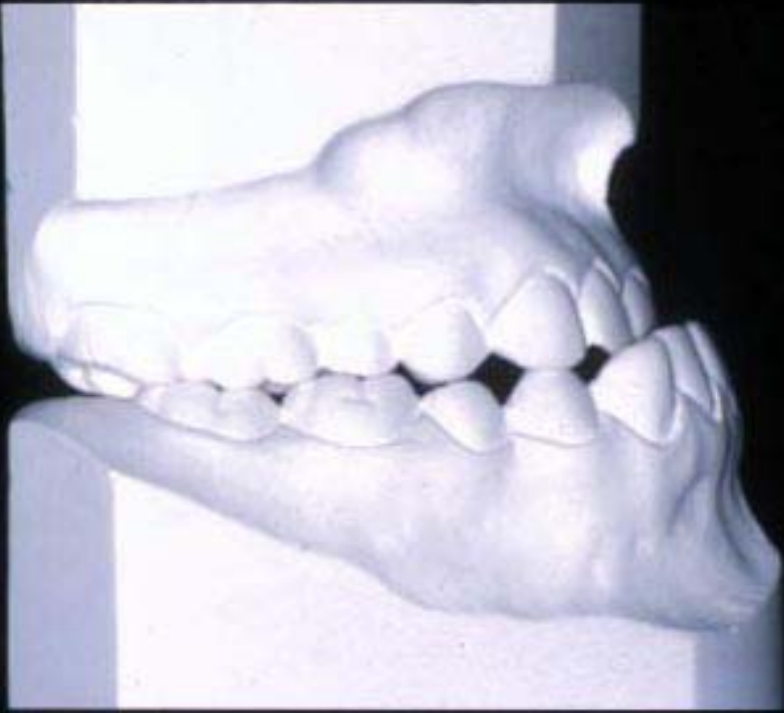
Class III (Lateral view)



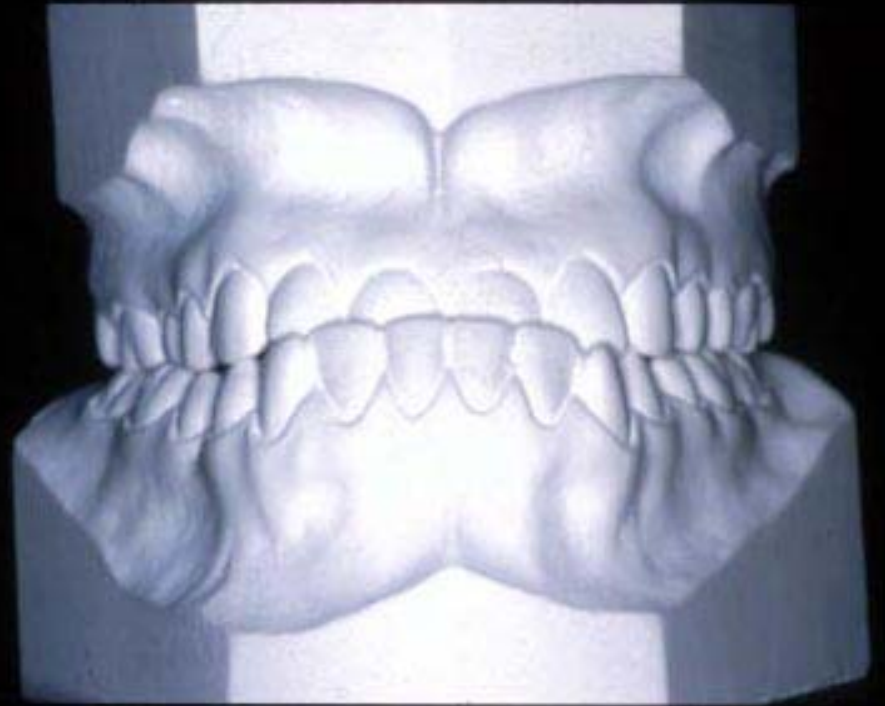
A100

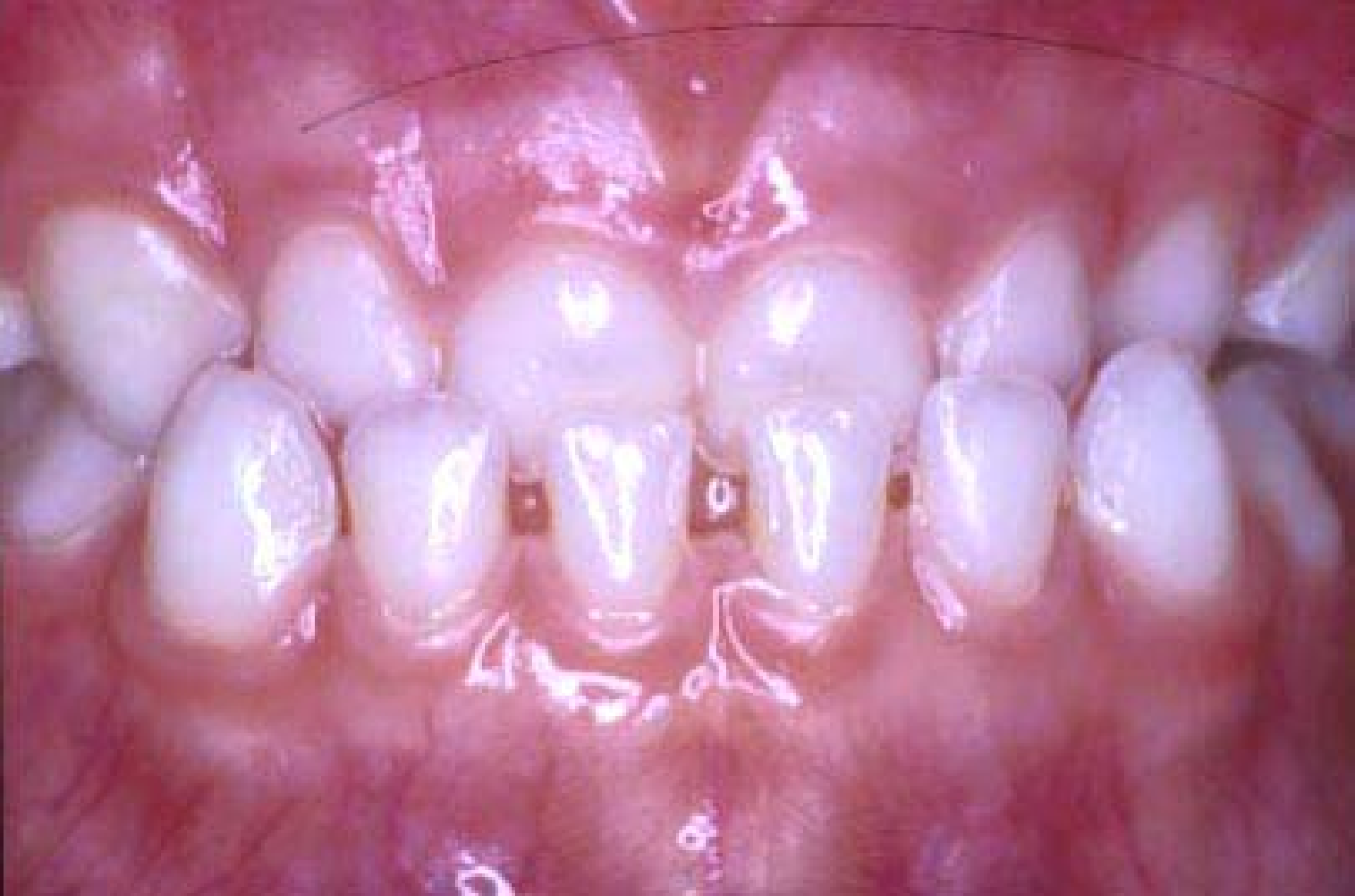Class III (Anterior view)

Class III malocclusion.



Sometimes called an ‘under-bite’.



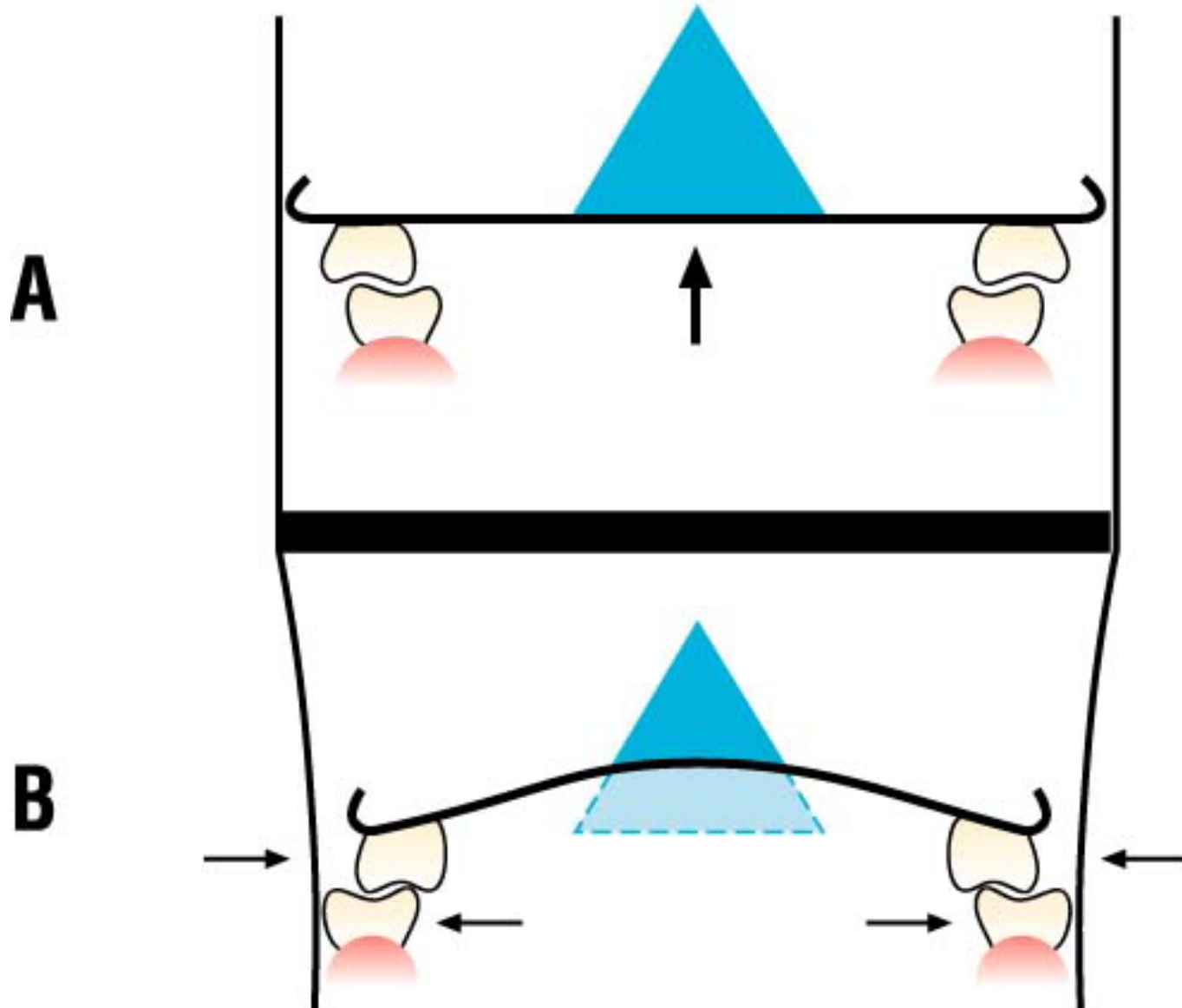


A102

Infant with Class III malocclusion.

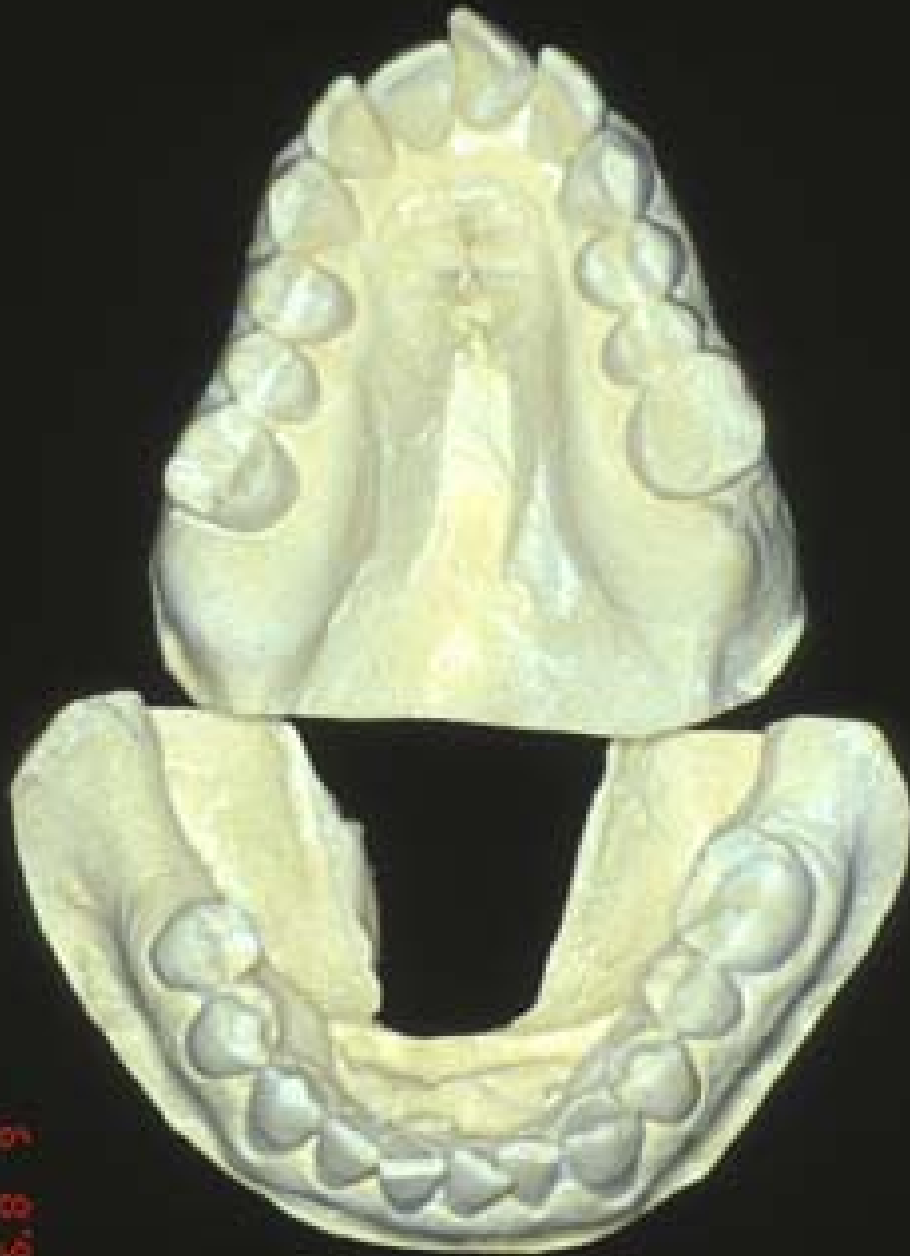Cross-bite

Palate Formation



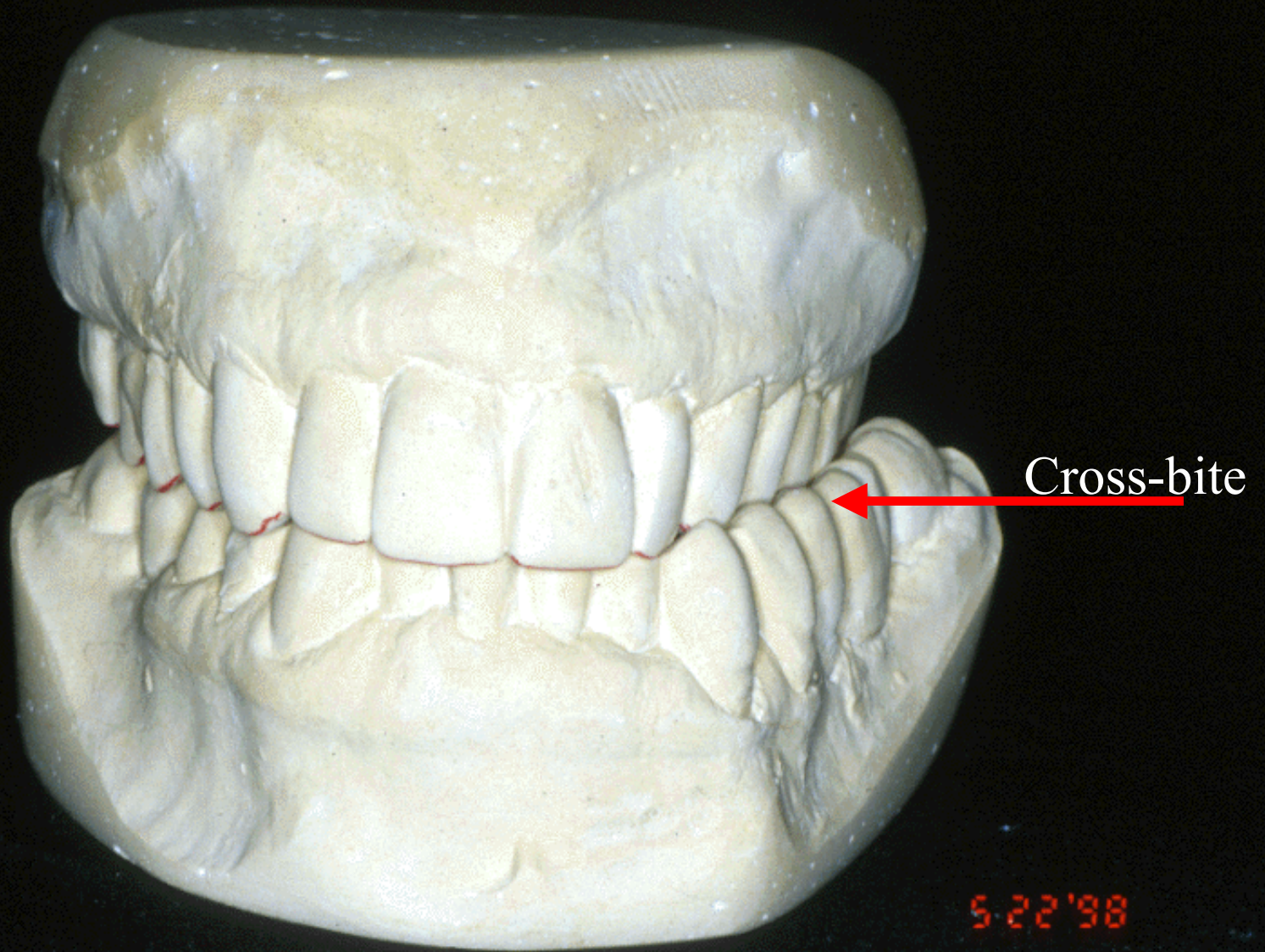
A104

In 'B', upper teeth are 'inside' lower teeth - due to a narrow arch.



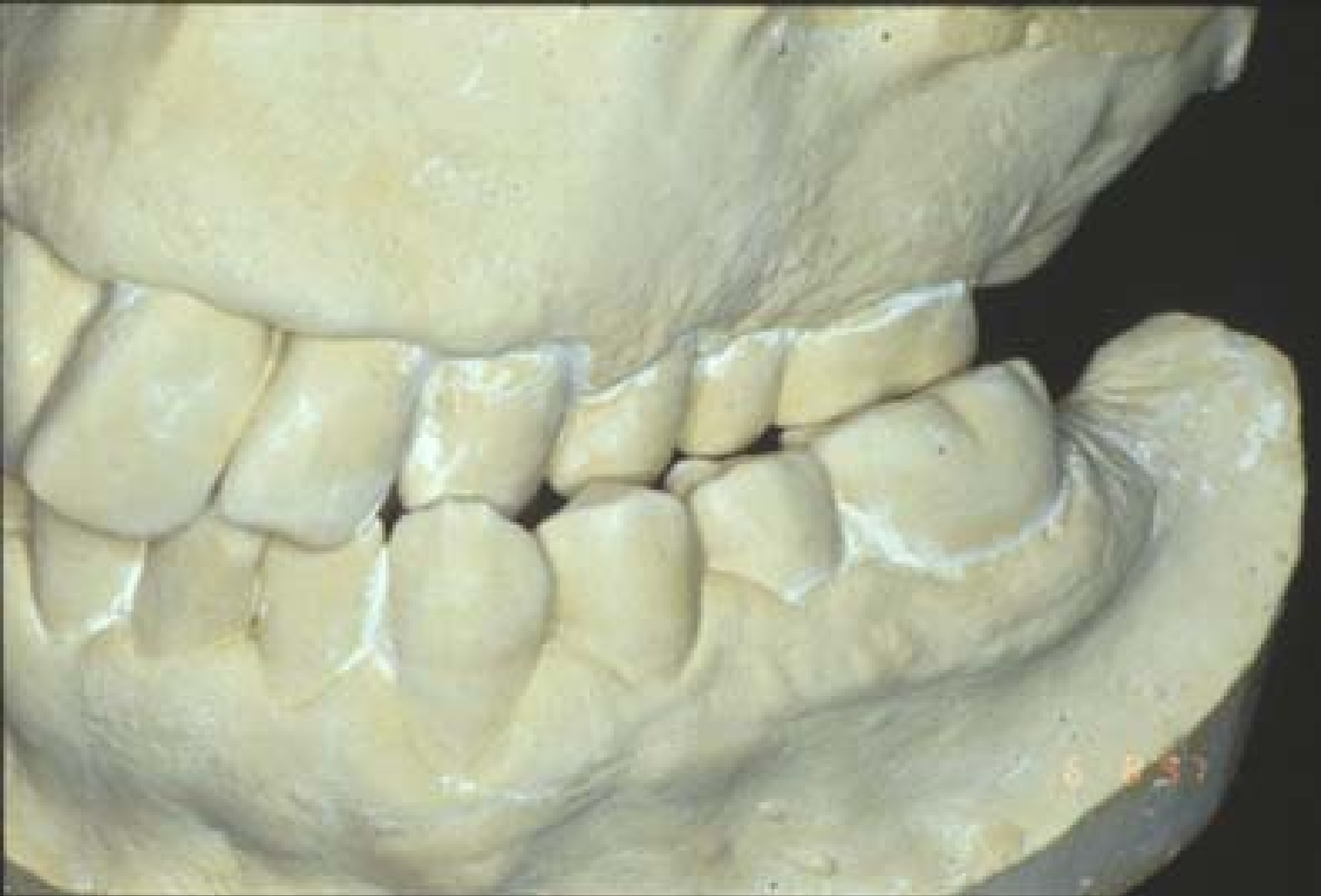Models demonstrating an example of a high palate and narrow upper arch.

6 8 '97



A106

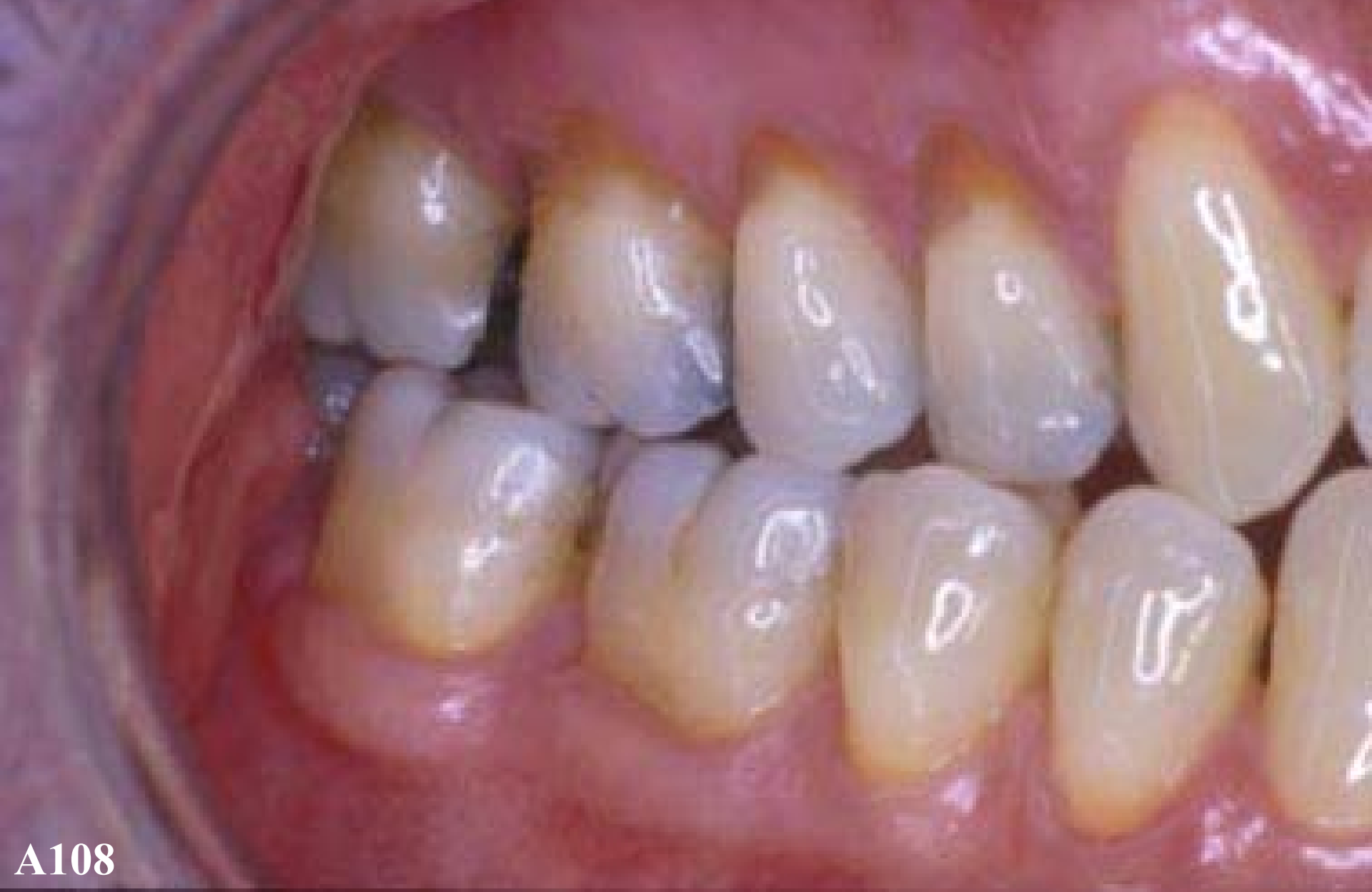Models demonstrating a cross-bite.



A107

Close-up of a cross-bite malocclusion.

Cross-bite has contributed to development of abfractions / recession and small tori developing on buccal #31.



AAPD Vision Statement (1996)

- “89% of youth, ages 12 - 17 years, have some occlusal disharmony.”
- “16% of youth have a severe handicapping malocclusion that requires mandatory treatment.”

Pediatr Dent, (J Amer Acad Pediatr Dent), Spec Issue:Reference Manual 1995-96,17(6).

Pacifier use (1997)

- 85% of children in her study used pacifiers by age one month. Children weaned from breastfeeding early use a pacifier more often than those who are breastfed longer.

Victora CG, Behague DP, et al. Pacifier use and short breastfeeding duration: cause, consequence, or coincidence? *Pediatr.* 1997 Mar;99(3):445-53.

Craniofacial Development

- Largest increment occurs within the first 4 years of life.
- Is 90% complete by 12 years of age

Shepard J, et al. Evaluation of the upper airway in patients with OSA, *Sleep* 1991;14(4):361-71.

End of section A

Brian Palmer, D.D.S.
Leawood, Kansas
December 2004.